

Curiositas

UNDERGRADUATE QUIZ

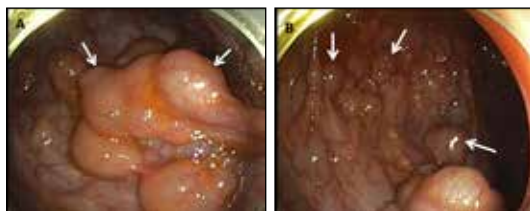

1. What are these people doing?
2. Why can't they do it the normal way?
3. Where are they doing it?

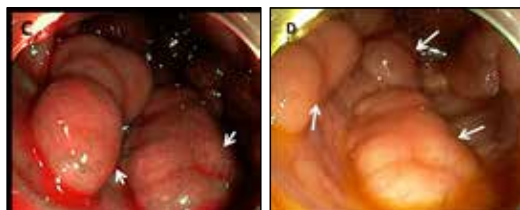S. Webb and J. Purvis (*Physicians and Members of the Irish Astronomical Association*).

POSTGRADUATE QUIZ

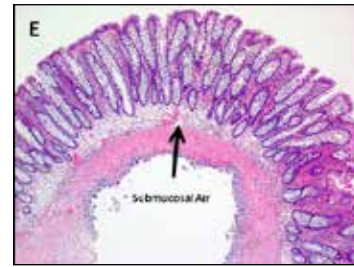
A 23 year old healthy male presented with intermittent bright red bleeding per rectum and non-specific colicky abdominal pain for over a year. There was no family history of colon cancer, familial polyposis syndrome or inflammatory bowel disease. On examination, he was overweight with normal vital signs. Physical examination was unremarkable as were his laboratory tests including inflammatory indices and complete blood count. An abdominal x-ray, CT scan and oesophago-gastro-duodenoscopy performed at an outside facility were normal, while colonoscopy revealed the colon to be matted with “polyps” in addition to internal haemorrhoids. He was referred for polypectomy or colectomy given the extensive nature of the disease.



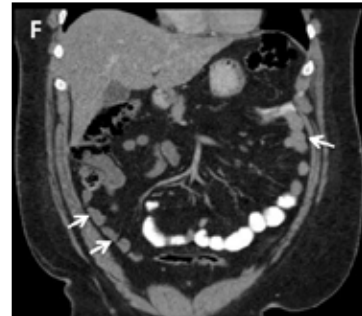(A, B): Repeat colonoscopy at our centre confirmed the “clustered polypoid” lesions.



(C, D): Mucosa showed normal pit pattern on white light and narrow band imaging.



(E) A representative sub centimetre lesion was removed using hot polypectomy, and the base clipped prophylactically. The lesion was noted to collapse at the time of removal.



(F) CT scan of the abdomen was unremarkable.

1. What is the most probable diagnosis?
2. How do you manage these lesions?

A. Perisetti¹, N. George¹, S. Raghavapuram¹, D. Banerjee², S. Taylor¹, B. Tharian¹. ¹Department of Gastroenterology, University of Arkansas for Medical Sciences, Little Rock, Arkansas, USA. ²Department of Medicine, University of Florida College of Medicine, Gainesville, Florida, USA.

AND FINALLY...



Image credit: Science Museum, London. CC BY. Accessible at <https://wellcomecollection.org/works/a9a66zy7>

What would have been stored in this jar and what was it used for?

P. Hamilton (*Clinical Lecturer, Centre for Medical Education, Queen's University Belfast and Honorary Consultant in Chemical Pathology, Department of Clinical Biochemistry, Belfast Health and Social Care Trust*).

ANSWERS See overleaf

CONSIDER CONTRIBUTING TO CURIOSITAS?

Please refer to "Curiositas: Guidelines for contributors" <http://www.ums.ac.uk/curiositas.html> and email umj@qub.ac.uk with your ideas and submissions.



Curiositas: Answers

UNDERGRADUATE QUIZ

1. Give yourself 1 mark if you said cardiopulmonary resuscitation (CPR) in space or on the International Space Station, 2 marks if you said CPR in microgravity or in parabolic flight/free fall, and 3 marks if you said: "Adopting the Evetts-Russomano position for performing CPR during parabolic flight". At the level of the International Space Station, there is still a little gravitational force exerted by the Earth on the astronauts and Station so technically, the correct term is microgravity. To simulate conditions aboard the International Space Station, a modified passenger jet can make a steep dive then pull up suddenly in a parabolic curve and this produces a few seconds of "weightlessness" when manoeuvres can be practised.
2. Without sufficient gravity, the rescuer performing chest compressions would be pushed away from the victim as per Newton's third law of motion (for every action, there is an equal and opposite reaction). The rescuer must be anchored to compress the chest effectively either by using available walls or fixed furniture (see image below) or if none is available, wrapping their lower limbs around the victim as an anchor point. This technique (shown on the previous page) was described by Evetts, Russomano and others in 2005¹ and is known as the Evetts-Russomano position.



Using a wall for stabilisation. Image source: <https://www.innovaspace.org/blog/cpr-in-space-not-such-a-weighty-task>

3. The modified passenger jets used for training in microgravity conditions are colloquially known as "Vomit Comets" due to the nauseating effect produced by lack of gravity on the inner ear.

¹Evetts, S.N. et al. *Basic life support in microgravity: evaluation of a novel method during parabolic flight. Aviation, Space and Environmental Medicine* 76, 506-10.

S. Webb and J. Purvis (Physicians and Members of the Irish Astronomical Association).

POSTGRADUATE QUIZ

1. The diagnosis is Pneumatosis Cystoides Intestinalis (PCI). It is a rare and unusual condition in which air gets trapped within the submucosa or subserosa¹. The aetiology may be idiopathic or related to a variety of conditions including obstruction,

adverse drug reactions, ischemic bowel disease, autoimmune disease and infection. PCI might show evidence of free air, bowel wall thickening, altered contrast mucosal enhancement, dilated bowel, soft tissue stranding, ascites or the presence of portal air². Histology of the tissue obtained during colonoscopy shows gas entrapment within the submucosa with normal overlying mucosa and no evidence of dysplasia. This can be seen preoperatively on abdominal x-ray or on CT which is considered the test of choice, though our case was unique with both being completely normal^{3,4}. Though the mechanism of air trapping is not entirely clear, injury to bowel wall or increased intraluminal pressure has been proposed as the possible pathogenesis⁴.

2. Recognition of such lesions in relatively asymptomatic individuals is important as they are managed conservatively without the need for polypectomy or colectomy in about 90% of cases⁵. The patient has been advised to seek immediate medical attention if he develops severe abdominal pain or any other complications.

¹Wu, S. and Yen, H. (2011) *Images in clinical medicine. Pneumatosis cystoides intestinalis. N Eng J Med* 365, e16.

²Wu, L. et al. (2013) *A systematic analysis of pneumatosis cystoides intestinalis. World J Gastroenterol* 19, 4973-8.

³Carter, P. and Wilson, H. (1955) *Pneumatosis cystoides intestinalis; case report of a Korean man. Surgery* 37, 255-9.

⁴Rachapalli, V. and Chaluvasetty, S. (2017) *Pneumatosis Cystoides Intestinalis. J Clin Diag Res* 11, TJ01-TJ02.

⁵Goel, A. et al. (2005) *Pneumatosis cystoides intestinalis. Surgery* 137, 659-60.

A. Perisetti¹, N. George¹, S. Raghavapuram¹, D. Banerjee², S. Taylor¹, B. Tharian¹. ¹Department of Gastroenterology, University of Arkansas for Medical Sciences, Little Rock, Arkansas, USA.

²Department of Medicine, University of Florida College of Medicine, Gainesville, Florida, USA.

AND FINALLY...

The picture shows a 'theriac jar', and a clue to its contents are the ornate handles which were designed to resemble intertwined serpents. The history of theriac was well described by Mez-Mangold¹, and a brief outline follows. In the first century B.C., Mithridates VI, King of Pontus and Armenia Minor developed a mixture of 54 substances that was used as a universal antidote for poisoning. After his defeat, the formula was modified by Andromachus, one of Nero's private physicians, to include 64 ingredients, one of the most important being the flesh of the viper. The mixture was known as 'Theriac of Andromachus' and was initially used as an antidote for snake bites, before taking on the status of a cure-all wonder drug. The substance was widely used until the late 18th century.

¹Mez-Mangold, L (1971) *A history of drugs. F. Hoffmann-La Roche & Co. Ltd., Basle, Switzerland.*

P. Hamilton (Clinical Lecturer, Centre for Medical Education, Queen's University Belfast and Honorary Consultant in Chemical Pathology, Department of Clinical Biochemistry, Belfast Health and Social Care Trust).



UMJ is an open access publication of the Ulster Medical Society (<http://www.ums.ac.uk>).

The Ulster Medical Society grants to all users on the basis of a Creative Commons Attribution-NonCommercial-ShareAlike 4.0 International Licence the right to alter or build upon the work non-commercially, as long as the author is credited and the new creation is licensed under identical terms.