

Curiositas

HISTORICAL QUIZ

The Belfast Medical Students' Association (BMSA) was established in 1886 and is one of the oldest and largest student societies at Queen's University Belfast (QUB). Below is an image of the front cover of the 'menu' from their 1958 annual Presidential dinner.

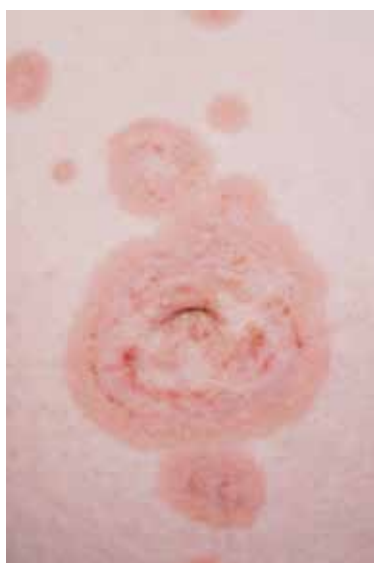


1. Who was the BMSA staff president that year?
2. Who gave the 'toasts' on the evening?
3. What was provided to attendees that would be frowned upon in today's medical world?

Dr B Donnelly, (Consultant Anaesthetist), Craigavon Area Hospital.

DERMATOLOGY QUIZ

A 33-year-old female who was 27 weeks pregnant presented with a two week history of an itchy rash that began in the peri-umbilical area and gradually spread to involve her trunk and limbs.



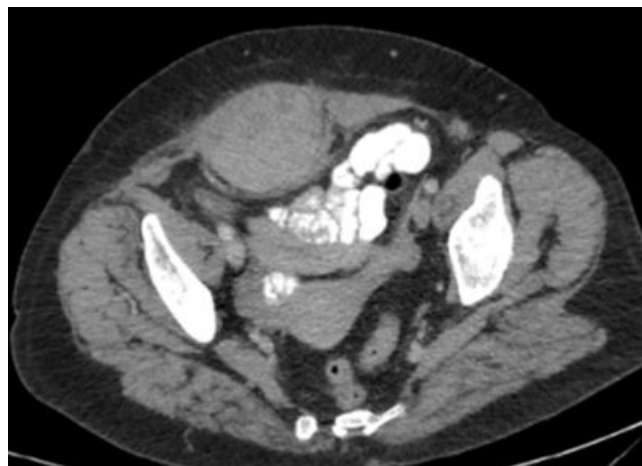1. What is the diagnosis?
2. What investigations are necessary?
3. How should this be managed?

J Moradzadeh (Medical student, Queen's University Belfast), Dr W Abdelrahman (Specialty registrar) and Dr D O'Kane (Consultant Dermatologist), Department of Dermatology, Royal Victoria Hospital, Belfast, Northern Ireland.

SURGICAL QUIZ

A 56-year-old female presented to the Emergency Department with a two-week history of increasing right iliac fossa pain. The pain was constant, localised and described as 10/10 in severity. She has a background of hypertension and was being treated for an acute exacerbation of chronic obstructive pulmonary disease. Abdominal examination revealed a 6 cm tender, superficial mass in the right iliac fossa with associated bruising in suprapubic region. She was systemically well.

A CT scan of abdomen was performed.



1. What is the diagnosis?
2. What is the treatment?
3. What is the pathophysiology of this condition?

M Kerr (Medical student, Queen's University Belfast) and Mr B Clements (Consultant Surgeon and Director of Emergency Surgical Unit, Royal Victoria Hospital, Belfast).

ANSWERS See overleaf

CONSIDER CONTRIBUTING TO CURIOSITAS?


Please refer to 'Curiositas: Guidelines for contributors' <http://www.ums.ac.uk/curiositas.html> and email umj@qub.ac.uk with your ideas and submissions.




Curiositas: Answers

HISTORICAL QUIZ

The BMSA staff president in 1958 was Professor George Dick. Professor Dick was appointed to the Chair of Microbiology at Queen's University Belfast in 1955. The menu that evening, and toasts, is shown below. As can be seen, quite a number of notable Northern Irish doctors were present that evening 60 years ago. I wonder what the current BMSA annual Presidential menu is like and will there be any notable doctors of the future present?

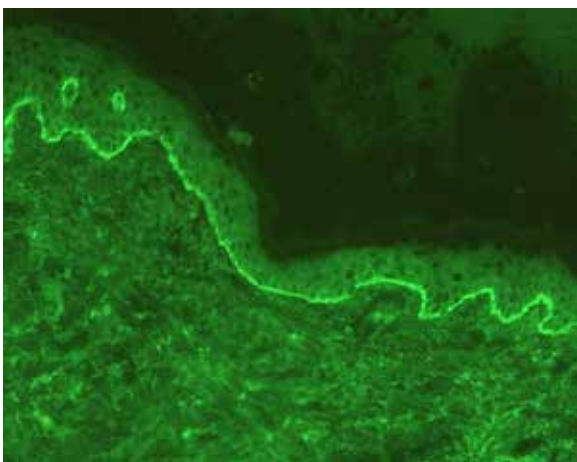


Finally, attendees were provided with cigarettes! At this time the dangers of smoking were simply not known and is so far removed from what happens today.



DERMATOLOGY QUIZ

1. The appearance of a pruritic, urticated rash during pregnancy that involves peri-umbilical skin is suggestive of pemphigoid gestationis. Foetal complications include premature delivery and transient blistering of the newborn.

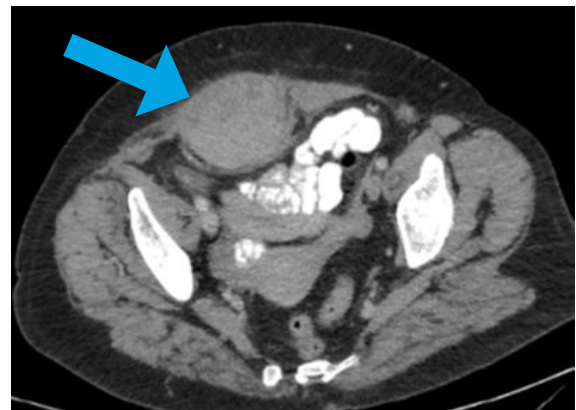

Skin biopsy for direct immunofluorescence: linear deposition of C3 along basement membrane which lies between epidermis and dermis.

2. Skin biopsy for histology and direct immunofluorescence are essential to confirm the diagnosis, along with serum testing for indirect immunofluorescence.
3. Topical corticosteroids and antihistamines are first-line agents to treat pemphigoid gestationis. For recalcitrant disease, systemic corticosteroids or steroid-sparing agents such as azathioprine or ciclosporin may be required. The choice will depend on whether the pregnancy is ongoing, since potential teratogenicity may limit the use of certain agents.

SURGICAL QUIZ

1. Rectus sheath haematoma – there is a large collection of organised blood in the right lower rectus abdominis muscle.



2. Analgesia combined with correction of any bleeding tendency. When the haematoma is expanding, interventional radiology should be considered to embolise the offending inferior epigastric vessels.
3. This usually occurs in elderly people when there is a background of chronic cough and use of anti-platelet or anti-coagulant drugs.

FURTHER READING:

HATJIPETROU, A., DIMITRIOS, A. and KASTANAKIS, M., 2015. Rectus sheath hematoma: A review of the literature. *International Journal of Surgery* 13, 267-71.



UMJ is an open access publication of the Ulster Medical Society (<http://www.ums.ac.uk>).

The Ulster Medical Society grants to all users on the basis of a Creative Commons Attribution-NonCommercial-ShareAlike 4.0 International Licence the right to alter or build upon the work non-commercially, as long as the author is credited and the new creation is licensed under identical terms.