

Case Report

# Radial Multi-Site, Longitudinal Multi-Polar Epicardial Left Ventricular Pacing In Tricuspid Valve Disease

Ernest W Lau,<sup>1</sup> Tony McEntee,<sup>2</sup> Kyle B Ashfield,<sup>1</sup> Alastair N Graham<sup>3</sup>

Accepted 21st February 2016

Provenance: externally peer-reviewed

## ABSTRACT

Tricuspid valve (TV) disease (which includes surgical repair) can impede transvenous endocardial right ventricular pacing. A lead crossing the TV can damage and be damaged by the valve, especially in the presence of mechanical prostheses (valve, annuoplasty ring, artificial chordae). Surgical epicardial lead placement requires sternotomy or thoracotomy and pericardotomy, with associated morbidity and mortality. Surgical epicardial leads perform less well than endocardial leads over time and may induce pericardial adhesions. With the possibility of radial and longitudinal multi-site pacing and pulse generators with versatile programmability, transvenous epicardial lead placement through the coronary sinus has become robust and reliable, and may provide the best approach for achieving permanent ventricular pacing in patients with TV disease.

## CASE HISTORY

A 75 year old male patient underwent tricuspid valve (TV) repair for severe regurgitation due to a flail anterior leaflet caused by chordal rupture after a motor vehicle accident. The anterior leaflet was re-attached to the papillary muscle with 4 artificial chordae made of sutures at the tip, and sutured to the septal and posterior leaflets at the base. The tricuspid annulus was buttressed with an annuoplasty ring with a gap over the septal region for atrio-ventricular node (AVN) and His bundle preservation. With these measures, tricuspid competence was achieved. Coronary artery bypass grafting was performed at the same time. The patient made an uneventful recovery from his cardiac surgery. However, he developed multiple arrhythmias, including sinus rhythm with complete heart block (CHB) and narrow complex escape rhythm (Fig 1a), paroxysmal atrial fibrillation (AF) with left (Fig 1b) and right (Fig 1c) bundle branch block (BBB), and paroxysmal atrial flutter with 2:1 A:V conduction (Fig 1d), over a 3 week period.

The management of the patient's multiple arrhythmias, which included both bradycardia and tachycardia, posed several clinical challenges. The patient displayed evidence of significant AVN and infra-Hisian conduction system disease, and hence required permanent pacing. Transvenous endocardial right ventricular (RV) pacing required crossing the TV with a lead, not ideal given the previous disease

and recent surgical repair. Surgical epicardial pacing required repeat sternotomy and pericardotomy, an especially unattractive option soon after cardiac surgery. Transvenous epicardial left ventricular (LV) pacing through the coronary sinus (CS) avoided these concerns and was deemed the best approach.<sup>1-3</sup>

The patient suffered from atrial flutter, but successful cavo-tricuspid isthmus ablation would be difficult and potentially dangerous in the presence of an annuoplasty ring (the ablation catheter needed to get under the ring; risk of ring dehiscence and para-prosthetic leakage). The patient was also likely to develop persistent or permanent AF over time, even with anti-arrhythmic drugs or ablation. Based on these considerations, it was decided the patient's atrial tachyarrhythmias would be best controlled by AVN ablation, especially as he already had a class I indication for permanent pacing. However, AVN ablation with the intentional induction of iatrogenic CHB placed a heavy burden on the reliability of permanent pacing. Transvenous epicardial LV pacing through the CS may fail post-operatively due to lead dislodgement, elevation of pacing threshold and phrenic nerve stimulation.<sup>4,5</sup> Even though the patient had normal LV function, it was decided the patient should have 2 leads placed in 2 different side branches of the CS if technically feasible in case one of the leads failed post-operatively.<sup>1</sup> Radially separated multi-site LV pacing may also provide an alternative form of cardiac resynchronization therapy (CRT).<sup>6</sup>

During permanent pacemaker implantation, the CS was found to have a large antero-lateral vein (ALV) and a middle cardiac vein (MCV) suitable for lead placement (Fig 2a). A quadripolar Quartet LV lead (St Jude Medical, Sylmar, CA, USA) was first positioned in the ALV with the tip advanced as distally as possible. The distal bipole (D1-M2, marked by § in Fig 2b) produced the best pacing parameters. A bipolar Quickflex  $\mu$  LV lead (St Jude Medical) was next positioned in the MCV with the tip advanced as distally as possible. However, all the distal lead tip positions near the

<sup>1</sup>Department of Cardiology and <sup>3</sup>Department of Cardiac Surgery, Royal Victoria Hospital, Belfast, Northern Ireland <sup>2</sup>PEI Surgical Limited, Dublin, Republic of Ireland

ernest.lau@btinternet.com

Correspondence to Dr E W Lau



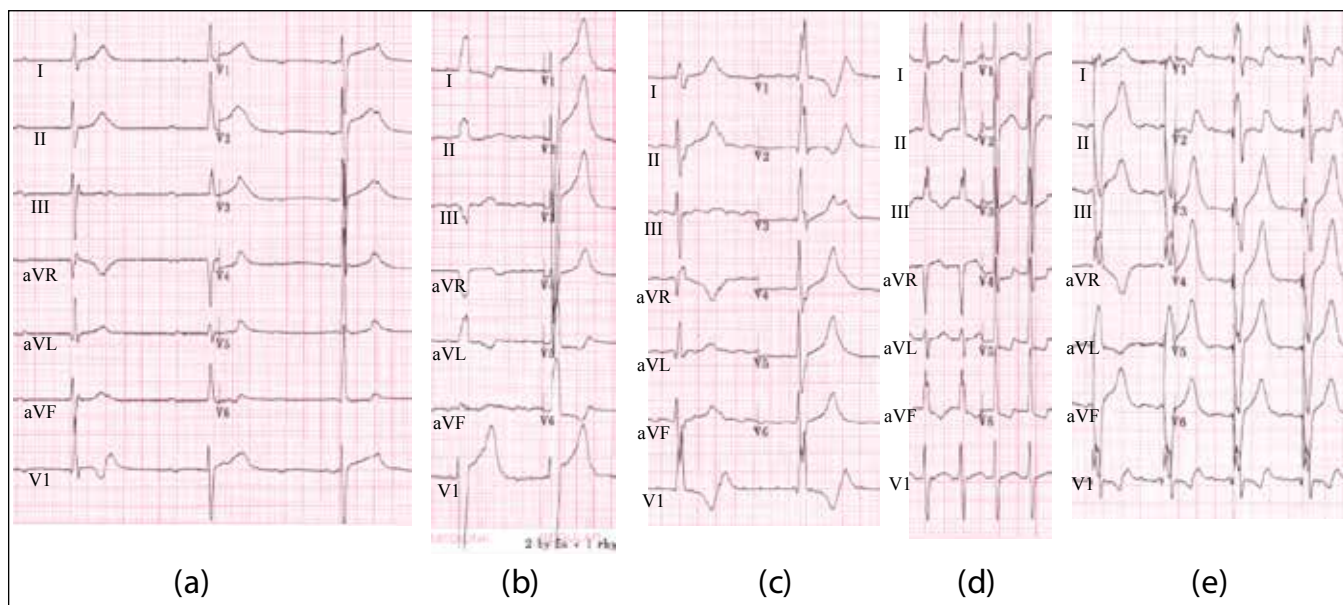


Fig 1. Electrocardiograms of arrhythmias and multi-site epicardial left ventricular pacing

(a) Complete heart block with narrow complex escape rhythm (b) Atrial fibrillation with left bundle branch block (c) Atrial fibrillation with right bundle branch block (d) Atrial flutter with 2:1 A:V conduction (e) Multi-site epicardial left ventricular pacing

apex (including into smaller second order side branches) failed to produce pacing capture of the LV. The only lead tip position that produced acceptable pacing parameters was very proximal (marked by \* in Fig 2b) with a high risk of dislodgement. Based on the existent knowledge of the pacing characteristics at different sites, it was decided a better long term outcome for the patient would be achieved by swapping the quadripolar and the bipolar LV leads around (Fig 2c). The most distal bipole (D1-M2) of the quadripolar lead delivered the largest sensed R wave at 9.7mV whereas the most proximal bipole (M3-P4) delivered the best pacing threshold of 1.25V at 0.4ms, with no diaphragmatic stimulation. The bipolar lead delivered a small sensed R wave and the best pacing threshold was 1.75V at 1ms with no phrenic nerve stimulation with the tip-to-can pulse configuration. The lead configuration of the 2 LV leads was accepted. An active fixation pacing lead was positioned in the right atrium. The leads were connected to the Allure Quadra biventricular pacemaker pulse generator (St Jude Medical), programmed to sense the R wave from the LV (the most proximal bipole of the quadripolar lead in the MCV) instead of the RV port. AVN ablation produced CHB with a right BBB pattern escape rhythm at around 45bpm. The patient felt substantially better post procedure with control of both his bradycardia and tachycardia (Fig 1e). The chest X-rays (Fig 3) and pacing check were all satisfactory. He was discharged home the day after his procedures.

## DISCUSSION

TV disease (which includes surgical repair) poses special problems for transvenous endocardial RV lead placement. A lead crossing the TV can induce stenosis<sup>7</sup> and regurgitation,<sup>8</sup> either through the physical presence of the lead or other biological processes such as fibrosis, thrombosis or infection.<sup>9</sup>

In this case, such a lead might interfere with the artificial chordae and cause recurrent TV regurgitation, defeating the main therapeutic aim of the original cardiac surgery. The TV leaflets might abrade against the lead, causing failure through outside-in abrasion of insulation<sup>10, 11</sup> and even conductor fracture,<sup>12</sup> especially in the presence of an annuloplasty ring.<sup>13</sup> Surgical epicardial lead placement requires sternotomy, thoracotomy and pericardotomy, with associated morbidity and mortality. Epicardial leads do not last as long as endocardial leads in general, and often suffer from a rising pacing threshold as well as insulation breach and conductor fracture over time.<sup>4, 14</sup> Epicardial leads may induce pericardial adhesions, making subsequent replacement difficult. In contrast, transvenous epicardial LV pacing through the CS avoids all these issues and may provide the best approach for patients with TV disease.

However, transvenous epicardial LV pacing through the CS suffers its own inherent limitations, including lack of suitable side branches, lead dislodgement, phrenic nerve stimulation, and less reliable pacing and sensing characteristics.<sup>4, 5</sup> The quadripolar lead was specifically developed to address these issues, and the Quartet was the first such lead commercially available. Similarly, the Allure Quadra is currently the only available biventricular pacemaker capable of accepting a quadripolar LV lead. One functional feature which proved pivotal in this case was the Allure Quadra's versatility in sensing the ventricles from either the RV port or the LV port (with the choice of multiple bipoles, independent of the pacing pulse configuration). Other manufacturers may wish to replicate this versatility in developing their comparable pulse generator models.

Transvenous epicardial LV pacing through the CS produces satisfactory long term performance and pacing outcomes.<sup>15</sup>



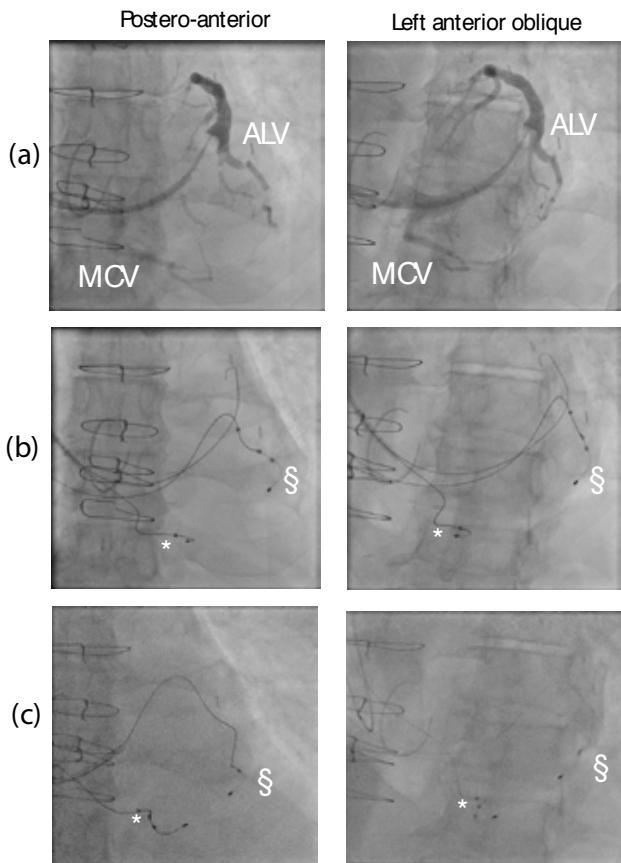


Fig 2. Radial multi-site longitudinal multi-polar epicardial left ventricular pacing

(a) Coronary sinus venogram revealed an antero-lateral vein (ALV) and middle cardiac vein (MCV) suitable for lead placement. (b) A quadripolar lead was placed in the ALV (best pacing site marked by §) and a bipolar lead in the MCV (best pacing site marked by \*). There was concern the bipolar lead might dislodge from the MCV given the proximity of the tip position. (c) The quadripolar and bipolar leads were swapped around to achieve the optimal combination of positional stability and pacing parameters for both leads.

With extension of operators' experience in CRT and advances in lead and pulse generator technologies offering ever expanding options, radial multi-site longitudinal multi-polar epicardial LV pacing should be the preferred approach for delivering permanent pacing to patients with TV disease.

Conflicts of interest: EWL consultancy for St Jude Medical

#### REFERENCES

- 1 Bos HS, Pop GA, Stel EA, van Gelder BM. Dual site coronary sinus pacing in a patient with an artificial tricuspid valve prosthesis. *Pacing Clin Electrophysiol.* 2004;27(10):1451-52.
- 2 Nguyen LS, Swaroop S, Prejean CA. Pacing in the middle cardiac vein in a patient with tricuspid prosthesis. *Pacing Clin Electrophysiol.* 2002;25(2):243-4.
- 3 Herre JM, Bullaboy CA, Derkac WM, Dow MT. Permanent transvenous

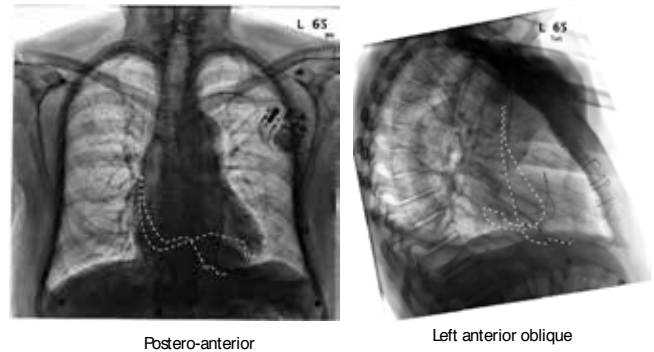


Fig 3. Chest X-rays showing bipolar and quadripolar leads in different side branches of the coronary sinus

The tricuspid annuloplasty ring can be clearly seen in the left anterior oblique projection.

dual-chamber pacing using the coronary sinus in a patient with a mechanical prosthetic tricuspid valve. *Pediatr Cardiol.* 2004;25(1):65-6.

- 4 Lau EW. Achieving permanent left ventricular pacing-options and choice. *Pacing Clin Electrophysiol.* 2009;32(11):1466-77.
- 5 Lau EW. Cardiac resynchronization therapy - the remaining challenges. *J Innovation Card Rhythm Manag.* 2012;3(Apr):747-57.
- 6 Padeletti L, Colella A, Michelucci A, Pieragnoli P, Ricciardi G, Porciani MC, Tronconi F, et al. Dual-site left ventricular cardiac resynchronization therapy. *Am J Cardiol.* 2008;102(12):1687-92.
- 7 Cassagneau R, Jacon P, Defaye P. Pacemaker lead-induced severe tricuspid valve stenosis: complete percutaneous extraction under extracorporeal life support. *Europace.* 2013;15(9):1248.
- 8 Baquero GA, Yadav P, Skibba JB, Banchs JE, Linton-Frazier LN, Lengerich EJ, et al. Clinical significance of increased tricuspid valve incompetence following implantation of ventricular leads. *J Interv Card Electrophysiol.* 2013;38(3):197-202.
- 9 Polewczyc A, Kutarski A, Tomaszewski A, Brzozowski W, Czajkowski M, Polewczyc M, et al. Lead dependent tricuspid dysfunction: Analysis of the mechanism and management in patients referred for transvenous lead extraction. *Cardiol J.* 2013;20(4):402-10.
- 10 Lau EW. External insulation breach near the tip of a single ventricular pacing lead. *J Innovation Card Rhythm Manag.* 2012;3(Feb):668-70.
- 11 Novak M, Dvorak P, Kamaryt P, Slana B, Lipoldova J. Autopsy and clinical context in deceased patients with implanted pacemakers and defibrillators: intracardiac findings near their leads and electrodes. *Europace.* 2009;11(11):1510-6.
- 12 Clarke B, Jones S, Gray HH, Rowland E. The tricuspid valve: an unusual site of endocardial pacemaker lead fracture. *Pacing Clin Electrophysiol.* 1989;12(7 Pt1):1077-9.
- 13 Hauser RG, Abdelhadi RH, McGriff DM, Kallinen Retel L. Failure of a novel silicone-polyurethane copolymer (Optim) to prevent implantable cardioverter-defibrillator lead insulation abrasions. *Europace.* 2013;15(2):278-83.
- 14 Tomaske M, Gerritse B, Kretzers L, Pretre R, Dodge-Khatami A, Rahn M, et al. A 12-year experience of bipolar steroid-eluting epicardial pacing leads in children. *Ann Thorac Surg.* 2008;85(5):1704-11.
- 15 Grimard C, Clementy N, Fauchier L, Babuty D. Ventricular pacing through coronary sinus in patients with tricuspid prosthesis. *Ann Thorac Surg.* 2010;89(6):e51-2.