

Case Report

Adrenal Sarcomatoid Carcinoma: A case report and review of the literature

David Mark¹, Clinton Boyd², Fiona Eatock¹

Accepted 23 January 2014

ABSTRACT

Adrenocortical sarcomatoid carcinoma (ASC) is an extremely rare variant of adrenocortical carcinoma (ACC). Its relative rarity and its characteristic histological pattern of both epithelioid and sarcomatoid components may pose diagnostic challenges which influence treatment. Here, we report a case of ASC in a 58 year-old man presenting with increasing abdominal pain and associated abdominal bloating with a large right adrenal mass detected by computed tomographic scan (CT). To our knowledge, only eleven prior cases of ASC have been reported in the literature. Here, we discuss the clinical, radiological and histopathological findings in our case, review the literature on ASCs and offer opinion on best management.

INTRODUCTION

Sarcomatoid carcinomas are tumours which contain both carcinomatous and sarcomatous differentiation. They have been identified in a variety of organ and tissue sites, including kidney, bladder, lung, breast and oesophagus.¹⁻³ Adrenocortical carcinoma (ACC) is an uncommon, aggressive malignancy with an estimated incidence of 1-2 per million population per year and, when untreated, a mean survival of 2.9 months.⁴⁻⁷ Adrenocortical sarcomatoid carcinoma or

carcinosarcoma (ASC) is a rare subgroup of ACC. To our knowledge, only eleven cases have been previously reported in the literature.⁸⁻¹⁷ We present the twelfth case and review the previous published literature to identify management strategies for the treatment of this rare tumour subtype.

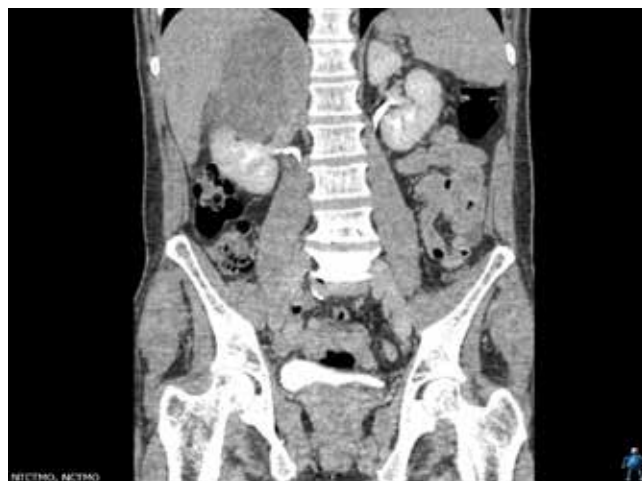

Fig 1b. Coronal Abdominal CT scan showing large right sided adrenal mass.

CASE REPORT

A 58-year-old caucasian male presented with a gradual onset of right sided loin pain over a number of months. A sudden increase in his pain prompted admission to a District General Hospital. The patient described a constant right loin pain with radiation to his groin. Initial urinalysis showed haematuria and a CT of his urinary system was arranged to investigate possible renal calculi. This identified an underlying adrenal mass. A further CT scan of the chest abdomen and pelvis confirmed a 9 x 7cm right sided adrenal mass.

The patient was transferred to a Regional Specialty Endocrine Surgery centre where hormone studies were performed

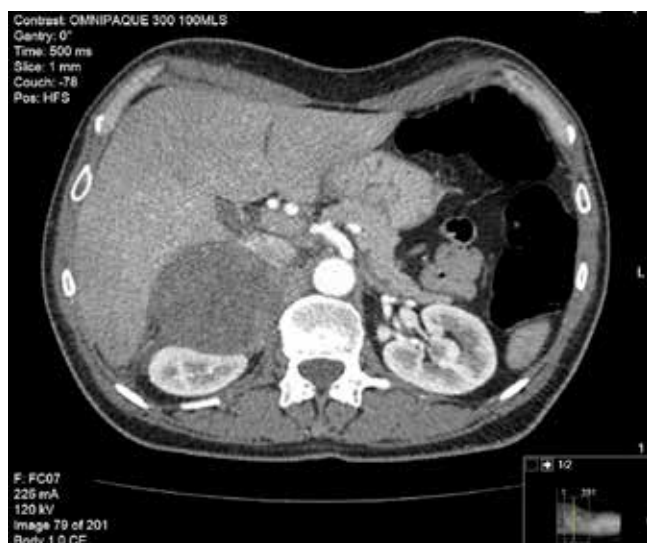

Fig 1a. Axial Abdominal CT scan showing large right sided adrenal mass.

1 Department of Endocrine Surgery, Belfast Health and Social Care Trust, Royal Victoria Hospital, Belfast, Northern Ireland

2 Department of Histopathology, Belfast Health and Social Care Trust, Royal Victoria Hospital, Belfast, Northern Ireland

Correspondence to: Fiona Eatock, Department of Endocrine Surgery, Royal Victoria Hospital, Grosvenor Road, Belfast BT12 6BA.

fiona.eatock@belfasttrust.hscni.net

to determine the potential functionality of the tumour. 24 hour urinary catecholamines, a dexamethasone suppression test, the Cortisol/Creatinine ratio and testosterone, dihydroxyepiandrosterone sulphate (DHEAS) and aldosterone levels were all within normal limits confirming the presence of a non-functioning adrenal mass. The patient went on to have an adrenalectomy and nephrectomy for the underlying lesion. The initial laparoscopic procedure was converted to open due to adherence of the mass to surrounding structures making for a difficult dissection from the inferior vena cava, inferior surface of the liver and the posterior abdominal wall musculature to which it was attached. Despite these difficulties a complete macroscopic excision was achieved. Post operatively the patient made an uneventful recovery. Given the extent of the primary tumour, and despite evidence of macroscopic excision, it was felt that the patient's greatest risk of relapse was at the site of surgery from a local recurrence. The patient went on to have 25 fractions of external beam radiotherapy at a dosage of 45 Gray (Gy). The benefits of chemotherapeutic agents were discussed with the patient and he and the oncology team felt that, given the absence of metastatic disease, any potential benefit was outweighed by potential morbidities of the treatment. At 16 months from initial diagnosis and treatment the patient was found to have evidence of metastatic disease to lung and brain. However a tissue diagnosis confirmed this to represent disease load from a second primary malignancy of lung origin. To date there is no evidence of local recurrence on CT PET or MRI of the previous adrenal malignancy.

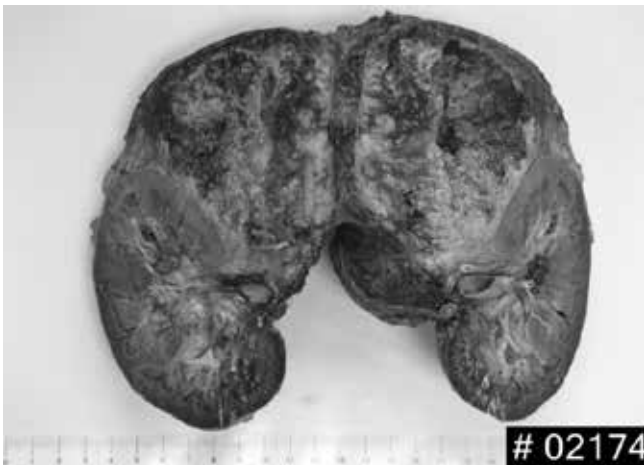

Fig 2. Specimen showing necrosis within the adrenal mass with no macroscopic evidence of extracapsular extension.

MACROSCOPIC EXAMINATION

The specimen weighed 573 g. The right kidney measured 12 x 7 x 5 cm and was compressed superiorly by a 12 x 5 x 6 cm adrenal mass. On sectioning of the specimen, the mass was found to be well-circumscribed with no macroscopic evidence of extracapsular extension. There was extensive haemorrhage and necrosis within the mass (Figure 2). The interface between the kidney and the mass was examined carefully by close serial sectioning. No communication between the two was identified.

MICROSCOPIC EXAMINATION

Histology of multiple representative sections showed a malignant tumour composed of diffuse sheets of epithelioid and spindle cells. There was marked nuclear atypia. No clear cell component was identified. Mitotic activity was brisk, at approximately 70 mitoses per ten high-power fields. The epithelioid and spindled areas were equally mitotically active. Numerous atypical mitoses were present. There was extensive necrosis. Tumour giant cells were present as well as a prominent lymphohistiocytic infiltrate (Figures 3a and 3b). No venous invasion was identified, and no evidence of extension into the surrounding soft tissues was seen. No normal adrenal gland tissue was identified. The kidney, which was removed en bloc, was histologically unremarkable. The area of kidney adjacent to the tumour was sampled in its entirety for histology. This showed no involvement by tumour.

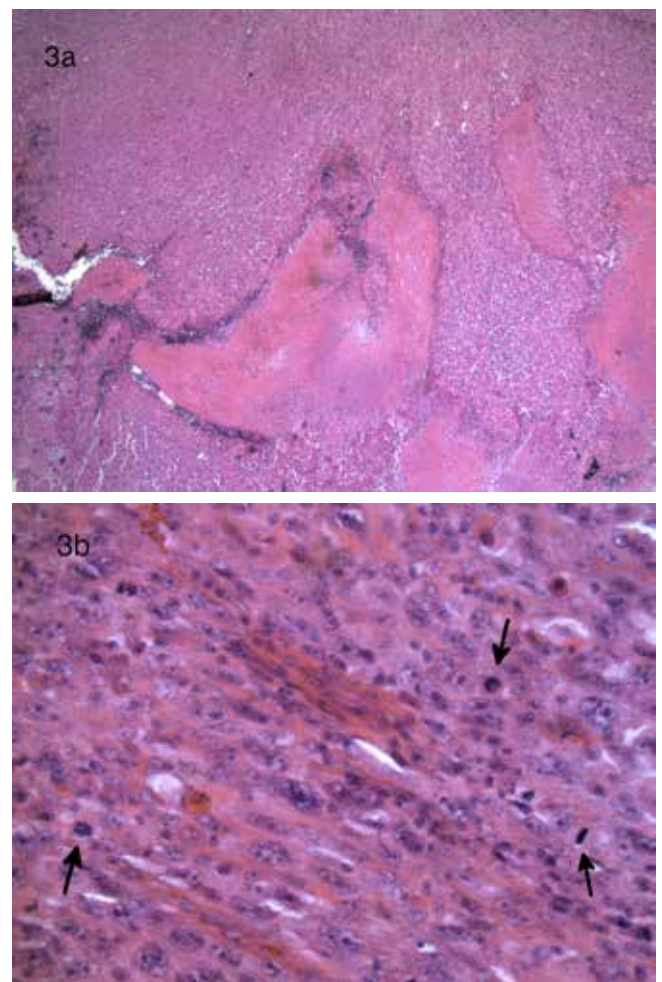


Fig 3a. Histopathology section (magnification x25) showing extensive necrosis and a prominent lymphohistiocytic infiltrate. Figure 3b: Section (magnification x200) showing a brisk mitotic activity and spindle cell components.

IMMUNOHISTOCHEMISTRY

The tumour cells showed strong, diffuse positivity with cytokeratins AE1/3 and Cam5.2. Cytokeratin 7 and epithelial membrane antigen showed patchy positivity. Weak positivity with synaptophysin was also present. The only other positive

TABLE 1:
Summary of ASC reported in the literature to date

Case No.	Reference	Age	Sex	Clinical Presentation	Metastatic Disease at Presentation	Size +/- Weight	Sarcomatous Component	Postoperative Survival
1	Okazumi et al. (1987)	46	M	Abdominal distention	No	14cm, 880g	Spindle cell	6 months
2	Collina et al. (1989)	69	F	Abdominal pain	No	11cm	Spindle cell	6 months
3	Decorato et al. (1990)	42	F	Abdominal pain	No	19cm, 1400g	Rhabdomyosarcoma	7 months
4	Fischler et al. (1992)	29	F	Weight loss, virilization	No	12.5cm, 610g	Rhabdomyosarcoma	8 months
5	Barksdale et al. (1993)	79	F	Hypertension	Invasion of Inferior Vena Cava	5cm, 199g	Osteosarcoma, chondrosarcoma	Not recorded
6	Lee et al. (1997)	61	M	Flank pain	Liver	12cm	Spindle cell	2 days
7	Strum et al. (2008)	31	M	Abdominal pain	No	12cm, 620g	Spindle cell	3 months
8	Coli et al. (2010)	75	F	Abdominal pain	No	15cm	Spindle cell	12 months
9	Sasaki et al. (2010)	45	M	Abdominal pain	Retroperitoneum, pancreas and duodenum	17cm, 2974g	Rhabdomyosarcoma	3 months
10	Feng et al. (2010)	72	M	Flank pain	No	No record	Spindle Cell	Not recorded
11	Thway et al. (2012)	45	M	Abdominal pain	Retroperitoneal nodes and pulmonary deposits	24cm, 6500g	Pleomorphic rhabdomyosarcoma	11 months
12	Current Study (2013)	58	M	Flank pain	No	12cm, 573g	Spindle cell	No evidence of metastatic adrenal disease at 17 months

immunohistochemical markers were CD10, vimentin (strong), desmin and S100 (weak). RCC marker antigen was negative. All other epithelial (including neuroendocrine) and mesenchymal markers were negative, as were melanocytic markers. MIB1 proliferative index was approximately 40%.

Due to these morphological and immunohistochemical findings, it was important to consider the possibility of sarcomatoid renal cell carcinoma. There was, however, no communication between the ipsilateral kidney and the adrenal mass. The contralateral kidney was radiologically normal. The most likely diagnosis on the basis of the clinical, radiological and pathological findings was therefore felt to be adrenocortical sarcomatoid carcinoma.

DISCUSSION

We present the twelfth documented case of Adrenocortical sarcomatoid carcinoma and a comprehensive summary of the previous literature. The age of presentation of ASC ranges from 29 - 79 years (mean 54.3 years). Although the number of cases reported is small, there is a female to male ratio of 1.4. Despite aggressive treatment, this variant of ACC has a poor prognosis, with the majority of patients succumbing to the disease within 3 - 12 months (mean 7 months) following

surgical intervention. The greatest determinants of early demise appear to be limited surgical resection and presence of distant metastatic spread at time of presentation.

All twelve cases can be defined as being carcinosarcoma or sarcomatoid carcinoma as suggested by Strum et al.¹⁴ Carcinosarcoma combines features of conventional ACC and areas of sarcoma which include heterologous elements such as rhabdomyosarcoma (skeletal muscle differentiation), chondrosarcoma and osteosarcoma. Sarcomatoid carcinoma, also referred to as carcinoma with sarcoma-like component, is mostly composed of malignant spindle cells without any identifiable heterologous differentiation and is often associated with areas of more conventional epithelial differentiation.¹⁴ Our case represents a sarcomatoid carcinoma since there was a prominent population of malignant spindle cells which did not show any recognizable differentiation. These findings were similar to six of the previous eleven reported cases.^{8,9,13,14,15,16} The other five previously reported cases were more appropriately classified as carcinosarcoma, with rhabdomyosarcoma identified as the sarcomatous component in three^{10,11,17}, pleomorphic rhabdomyosarcoma in one¹⁸ and the final case showing elements of both osteosarcoma and chondrosarcoma.¹²

The rarity of these subgroups of ACC presents a histopathological challenge, particularly when applying the Weiss scoring system which has remained the most widely used means of assessing the potential for malignancy in adrenocortical neoplasms.^{20,21} The presence within a tumour of a sarcomatous or sarcomatoid component seems to be a predictor of shorter survival in ACC. Sarcomatoid histology is not accounted for in the Weiss system, which may lead to confusion when dealing with these tumours, particularly with regards to the proportion of diffuse architecture required.²² In this setting, Sturm and colleagues have proposed that a sarcomatoid component should be well circumscribed and represent at least 10% of the tumour bulk in order to establish this unusual diagnosis.^{14,22} Whilst this rare tumour subtype represents a significant clinical, radiological and histopathological diagnostic challenge, its prompt identification will ensure the best long term prognosis in a cancer that requires a maximally aggressive management approach.

Given the rarity of this tumour subtype an evidence-based consensus regarding best oncological treatment is difficult. The use, or documented use, of adjuvant treatments in the previous cases was variable. In eight cases no additional treatments were reported^{8,10,12,13,15,16,17,18} the remaining three cases opted mainly for chemotherapy with a combination of Cisplatin and Etoposide reported by Collina⁹ and Fischler et al¹¹ and Cisplatin used in isolation by Strum et al.¹⁴ Fischler also reported additional adjuvants with Mitotane in combination with chemotherapeutics. Only one of the previous cases used radiotherapy but it is assumed, given the radiation doses described and the context of bony metastatic disease, that this was for symptomatic palliation only.⁹ Our patient was clinically well 14 months following surgical intervention with follow up CT imaging showing no evidence of local recurrence. Our patient has been the longest survivor when compared to previous cases however he has unfortunately gone on to develop evidence of malignant spread from a second primary lung malignancy. We maintain that the greatest chance of long term survival from adrenal sarcomatoid carcinoma to be early detection prior to metastatic spread, radical complete excision and adjuvant external beam radiotherapy in an attempt to prevent local disease recurrence. Despite these findings our patient has been the longest survivor when compared to previous cases and we therefore surmise that the greatest chance of long term survival to be early detection prior to metastatic spread, radical complete excision and adjuvant external beam radiotherapy in an attempt to prevent local disease recurrence.

All authors have no conflict of interest

REFERENCES

1. Guarino M, Tricomi P, Giordano F & Cristofori E. Sarcomatoid carcinomas: pathological and histopathogenic considerations. *Pathology*. 1996; **28**: 298-305.
2. Meis JM, Ordóñez NG & Gallagher HS. Sarcomatoid carcinoma of the breast: an immunohistochemical study of six cases. *Virchows Archiv*. 1987; **410**: 415-421.
3. Weidner N. Sarcomatoid carcinoma of the upper aerodigestive tract. *Seminars in Diagnostic Pathology*. 1987; **4**: 157-168.
4. Tauchmanová L, Colao A, Marzano LA, Sparano L, Camera L, Rossi A, Palmieri G, Marzano E, Salvatore M, Pettinato G, Lombardi G & Rossi R. Adrenocortical Carcinomas: Twelve-year Prospective Experience. *World J Surg*. 2004; **28**: 896-903.
5. Hanna NH & Kennedy E. Advances in the management of adrenal tumours. *Curr Opin Oncol*. 2000; **11**: 49-53.
6. Thompson NW & Cheung PSY. Diagnosis and treatment of functioning and nonfunctioning adrenocortical neoplasms including incidentalomas. *Surg Clin North Am*. 1987; **67**: 423-436.
7. Søreide JA, Brabrand K & Thoresen SØ. Adrenal cortical carcinoma in Norway, 1970-1984. *World J Surg*. 1992; **16**: 663-668.
8. Okazumi S, Asano T, Ryu M, Nagashima T, Odaka M, Isono K & Nishizawa T. Surgical resection of adrenal carcinoma extending into the vena cava, right atrium and ventricle: case report and review of the literature. *Nippon Geka Gakkai Zasshi*. 1987; **88**: 231-238.
9. Collina G, Maldarizzi F, Betts CM & Eusebi V. Primary sarcomatoid carcinoma of the adrenal gland. First case report. *Virchows Arch A Pathol Anat Histopathol*. 1989; **415**: 161-167.
10. Decorato JW, Gruber H, Petti M & Levowitz BS. Adrenal carcinosarcoma. *J Surg Oncol*. 1990; **45**: 134-136.
11. Fischler DF, Nunez C, Levin HS, McMahon JT, Sheeler LR & Adelstein DJ. Adrenal carcinosarcoma presenting in a woman with clinical signs of virilization. A case report with immunohistochemical and ultrastructural findings. *Am J Surg Pathol*. 1992; **16**: 626-631.
12. Barksdale SK, Marincola FM & Jaffe G. Carcinosarcoma of the adrenal cortex presenting with mineralocorticoid excess. *Am J Surg Pathol*. 1993; **17**: 941-945.
13. Lee MS, Park IA, Chi JG, Ham EK, Lee KC & Lee CW. Adrenal carcinosarcoma—a case report. *J Korean Med Sci*. 1997; **12**: 374-377.
14. Sturm N, Moulai N, Laverriere MH, Chabre O, Descotes JL & Brambilla E. Primary adrenocortical sarcomatoid carcinoma: case report and review of literature. *Virchows Arch*. 2008; **452**: 215-219.
15. Coli A, Di Giorgio A, Castri F, Destito C, Wiel Marin A & Bigotti G. Sarcomatoid carcinoma of the adrenal gland: a case report and review of literature. *Pathol Res Pract*. 2010; **206**: 59-65.
16. Feng YC, Yang ZG, Chen TW, Su XY, Deng W & Wang QL. Adrenal sarcomatoid carcinoma: a rare case depicted on multi-detector row computed tomography. *Indian J Med Sci*. 2010; **64**: 137-40.
17. Sasaki K, Desimone M, Rao HR, Huang GJ & Seethala RR. Adrenocortical carcinoma: a case report and review of the literature. *Diagn Pathol*. 2010; **5**: 51.
18. Thway K, Olmos D, Shah C, Flora R, Shipley J & Fisher C. Oncocytic Adrenal Cortical Carcinosarcoma With Pleomorphic Rhabdomyosarcomatous Metastases. *Am J Surg Pathol*. 2012; **36**: 470-477.
19. DeLellis RA, Lloyd RV, Heitz PU & Eng C (2004) World Health Organization classification of tumours. Pathology and genetics of tumours of endocrine organs. IARC, Lyon.
20. Papotti M, Libe R, Duregon E, Volante M, Bertherat J & Tissier F. The Weiss Score and Beyond—Histopathology for Adrenocortical Carcinoma. *HORM CANC*. 2011; **2**: 333-340.
21. Weiss LM. Comparative histologic study of 43 metastasizing and nonmetastasizing adrenocortical tumors. *Am J Surg Pathol*. 1984; **8**: 163-9.
22. De Krijger RR & Papanthomas TG. Adrenocortical neoplasia: evolving concepts in tumorigenesis with an emphasis on adrenal cortical carcinoma variants. *Virchows Arch*. 2012; **460**: 9-18.