

Curiositas

RESEARCH

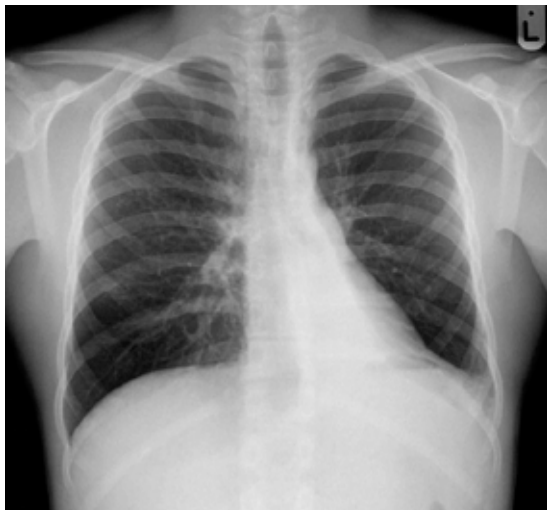Medical knowledge is always changing. However, one would be forgiven for supposing that the normal anatomy of the human body is fully understood. Students of the discipline memorise anatomical terminology, origins, insertions and relations for the most intricate of body structures. Modern medical imaging modalities allow the demonstration of minute structures that bring memories from the dissection room and anatomy textbooks to life. The ligaments of the knee have always been fundamental in the study of the function of this large joint. Indeed the integrity of the cruciate and lateral collateral ligaments are tested during the routine physical examination of the lower limb musculoskeletal system. A recent report by Claes et al suggests that future anatomy students will have more to learn about the knee than their predecessors, since the researchers have identified another ligament. In a cadaveric dissection study, 40 out of 41 knees studied had an extra ligament present. The appropriately-named 'anterolateral ligament' was shown to consistently run obliquely from the lateral femoral epicondyle to the anterolateral aspect of the proximal tibia. It may have a role in the control of internal tibial rotation. The precise role of the ligament, how it is damaged in injury and how its repair might influence recovery remain to be investigated.

This recent research paper should serve to remind us all of the dynamism of medical knowledge. What we consider to be medical fact today might well be challenged by the research of tomorrow.

Claes, S., Vereecke, E., Maes, M., Victor, J., Verdonk, P., Bellemans, J. Anatomy of the anterolateral ligament of the knee. *Journal of Anatomy* 2013; 223(4)321-8.

MEDICAL STUDENT QUIZ

This young adult male patient presented to his GP with shortness of breath and a mild cough. He has no past medical history. What is the diagnosis?

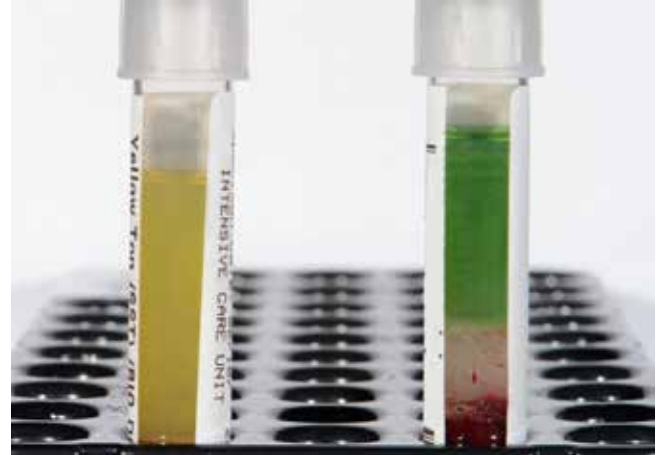

Dr Ian Bickle, Consultant Radiologist, Raja Isteri Penigran Anak Saleha Hospital, Bandar seri Begawan, Brunei Darussalam.

CONSIDER CONTRIBUTING TO CURIOSITAS?
Please refer to 'Curiositas: Guidelines for contributors' <http://www.ums.ac.uk/curiositas.html> and email curiositas@ums.ac.uk with your ideas and submissions

POSTGRADUATE QUIZ

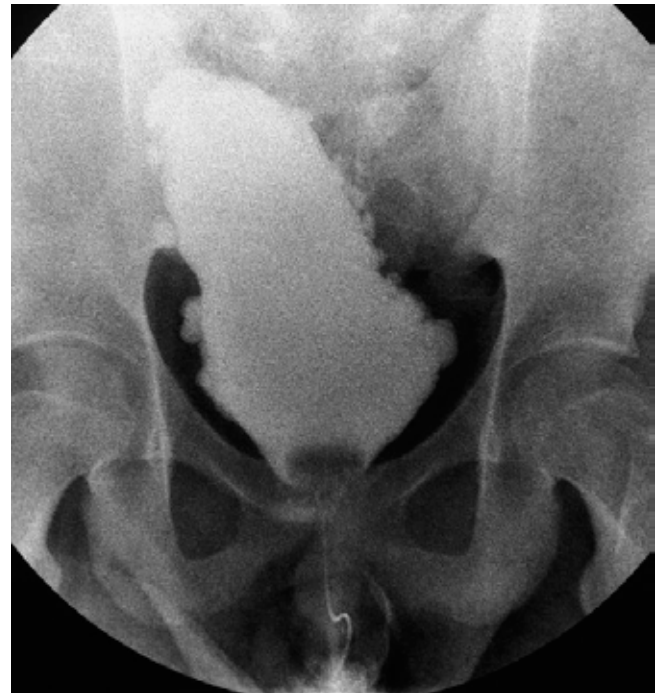A female patient had blood taken shortly after undergoing a surgical procedure. When the blood sample was centrifuged the laboratory staff were surprised to note an unusual appearance to the serum. What procedure has the patient had, and what would account for the distinctive colour? The photograph shows the patient's sample (right) alongside a normal sample (left).



Dr Paul Hamilton (Specialty Registrar, Chemical Pathology), Mr David McBride (Biomedical Scientist), Mr Stephen Kirk (Consultant Surgeon), Ulster Hospital Dundonald, South Eastern Health and Social Care Trust, Northern Ireland.

AND FINALLY.....

This long standing neurology patient underwent a cystogram as part of their care with respect to ongoing urinary symptoms. What festive description is given to this bladder and what is the usual cause?



Dr Ian Bickle, Consultant Radiologist, Raja Isteri Penigran Anak Saleha Hospital, Bandar seri Begawan, Brunei Darussalam.

ANSWERS See overleaf.

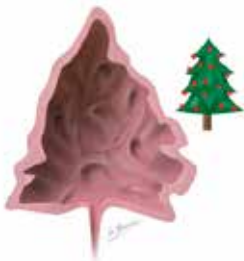Curiositas: Answers

POSTGRADUATE QUIZ

This patient underwent breast surgery and a sentinel node biopsy performed shortly before the blood was taken. As part of the biopsy procedure, a dye (Patent Blue®) is injected into the lymphatic system. After injection, patients are commonly noted to take on a grey appearance, and urine has a green discoloration. A striking green appearance of the serum has also been reported, but is seen uncommonly in the laboratory. Green serum has also been reported in association with copper-containing compounds in the blood, bile pigments and various imaging dyes (Randell, 2011).

Randell, P. (2011) Green serum: should the laboratory be worried? *The Biomedical Scientist*, June 2011.

AND FINALLY.....



Christmas comes only once a year, but this bladder pathology is observed even less frequently - the 'Christmas tree bladder'. The description is self-explanatory with the bladder having the appearance of a Christmas (or fir/ pine-cone) tree. The bladder has an elongated shape with a pointed dome, along with diverticular out-pouchings due to a trabeculated bladder wall that appear like barbells hanging on the tree. It is almost always the result of a severe

long-standing neurogenic bladder.

Follow this link for further information about this clinical case:

[www.ums.ac.uk/curiositas/083\(1\)cur.pdf](http://www.ums.ac.uk/curiositas/083(1)cur.pdf)

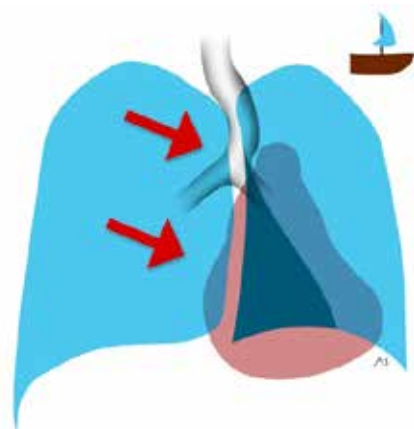
(Art work kindly produced for *Curiositas* by Dr Matthew Skalski, Diagnostic Imaging Resident, Southern California University of Health Sciences, USA. Radiographic images courtesy of Dr Ian Bickle)

MEDICAL STUDENT QUIZ

The sign of left lower lobe collapse to identify is the triangular shaped density in the left retrocardiac position, representing the lobe collapsed towards the midline. The triangular shape, given the term 'sail sign' has its straight edge medially, with the base inferiorly and the apex towards the hilar region. The origin of the term 'sail sign' lies in its resemblance to the sail of a yacht.

Follow this link for further information about this clinical case:

[www.ums.ac.uk/curiositas/083\(1\)cur.pdf](http://www.ums.ac.uk/curiositas/083(1)cur.pdf)



(Art work kindly produced for *Curiositas* by Dr Matthew Skalski, Diagnostic Imaging Resident, Southern California University of Health Sciences, USA. Radiographic images courtesy of Dr Ian Bickle)