

Case Report

# Panspinal epidural and psoas abscess with secondary cervical disc space infection

Alireza Shoakazemi, Amit Amit, Nashid Nooralam, Ashraf Abouharb, Mark Gormley, Steven McKinstry

Accepted 27 September 2012

## INTRODUCTION

Psoas<sup>9</sup> and epidural spinal abscesses<sup>2,6</sup> have been described as relatively rare conditions. The incidence of epidural spinal abscess, however, has doubled in the recent two decades, reaching 1 in 10000 hospital admissions<sup>8</sup>. Early diagnosis and management of these two pathologies, especially when presenting with insidious and vague symptoms, require a high degree of suspicion. In this case, unusual evolving cervical disc space infection was also noted

0/5 in all 4 limbs) and absence of reflexes in all limbs. Cranial nerves were intact on examination.

He was transferred to the regional neurosurgical unit about 48 hours after his initial presentation with neck pain followed by a rapid onset of quadriplegia. He was intubated and ventilated because of deteriorating respiratory drive and hypoxia. Urgent MRI scan of cervical spine showed an extensive epidural fluid collection and abnormality of the C5/6 disc space. Because of the lack of oedema in the adjacent marrow or increased signal

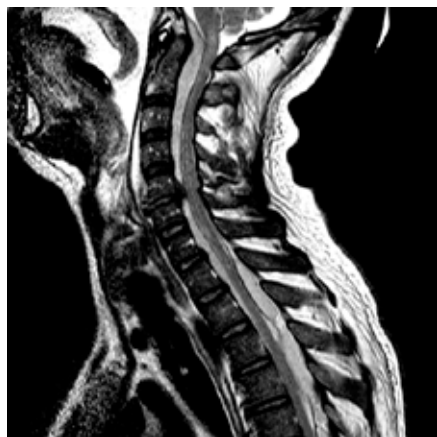

Figure 1(a)

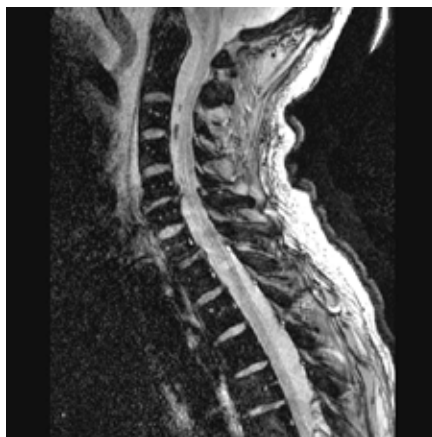

Figure 1(b)

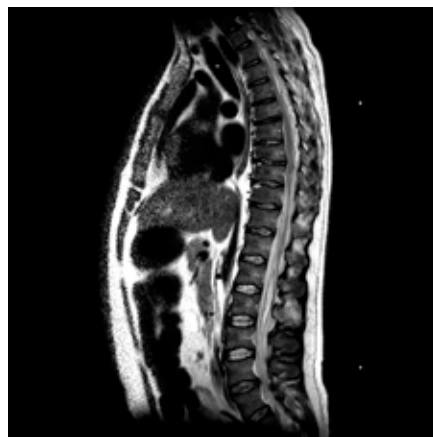


Figure 1(c)

*Fig 1.* Sagittal T2-weighted (a) and STIR images (b) of the cervical spine and sagittal T2-weighted image of the dorsal spine (c) on admission, showing epidural fluid collection extending entire length of spine. Note disc space narrowing and disc protrusion at C5/6, with anterior osteophyte formation, and lack of evidence of oedema in adjacent marrow. A prevertebral fluid collection is also present.

## CASE PRESENTATION

A 44-year-old man presented to the local hospital with a five-day history of neck pain, neck spasm, anorexia and malaise, on a background of recent lower back manipulation by a physiotherapist. For the previous few days he had complained of bilateral sciatica episodes, tingling sensation in both hands and night sweats. On clinical examination he was found to have high temperature (T=38.7) with no abnormal neurological signs apart from torticollis. Haematological examination showed raised CRP (CRP=246) and neutrophil leucocytosis (WBC=28.7). A blood culture was sent and then the patient was empirically commenced on broad-spectrum antibiotics. While waiting for further investigation on the ward he developed a transient episode of limb weakness followed by quadriplegia with a sensory level at T5 (power

in the disc on the T2-weighted and STIR (short tau inversion recovery) images, initially it was felt that these changes were be due to degenerative change rather than infection.

Therefore, further scans of the whole spine were performed after intravenous Gadolinium. Axial scans were performed of the dorsolumbar region. These showed peripheral enhancement of the epidural collection, consistent with abscess, and also extensive peripherally enhancing abscesses in the paraspinal muscles with extension into the intervertebral foramina (Figure 2). Further scans of the neck

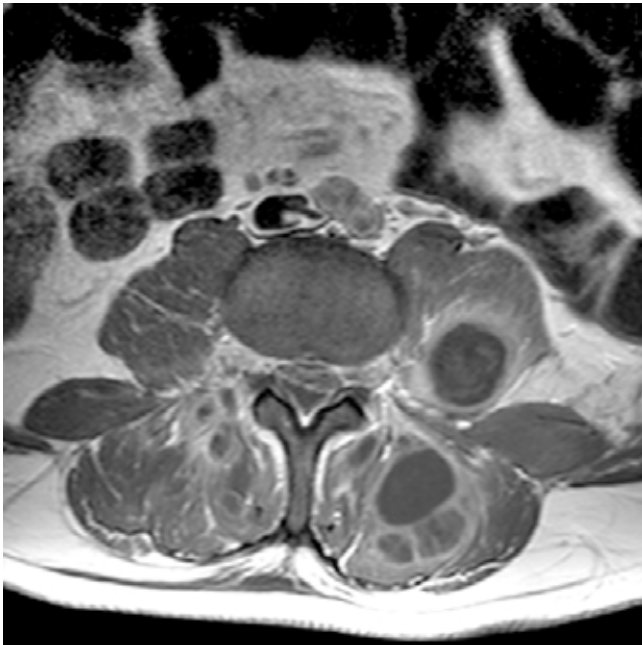
Department of Neurosurgery, regional Neuroscience Unit, Royal Victoria Hospital, Belfast, United Kingdom, BT12 6BA

Correspondence to Alireza Shoakazemi

ashoakazemi@yahoo.com

were not performed as the patient became haemodynamically unstable and had to be removed from the scanner. Therefore, the presumptive diagnosis was epidural abscess due to extension from paraspinal abscess, possibly secondary to recent manipulation of the lumbar spine.

His platelet count on admission was 69 million per millilitre (the patient was a known case of sticky platelet syndrome), and following transfusion of 4 units of platelets he underwent C3-C6 laminectomy and abscess drainage using an epidural catheter to ensure complete drainage of the abscess proximal and distally. A second incision was made in mid-thoracic region for T3-T5 laminectomy and drainage of epidural abscess. A third incision was made in lumbar region (L1-L4 level) and through para-vertebral approach to neural foramina and accessing the spinal canal we drained the epidural abscess at the same time as draining the psoas and paraspinal muscle abscess with insertion of a drain. We drained a mixture of clots and pus from the paraspinal muscles.



*Fig 2.* Axial T1-weighted scan of lumbar spine following intravenous Gadolinium, at the time of admission. Note peripherally enhancing epidural and paraspinal abscesses, extending into intervertebral foramina.

Post operatively he was transferred to ICU and was commenced on empirical antibiotic treatment (Flucloxacillin, Rifampicin, Gentamicin) and Dexamethasone (2 mg bd).. The cultures (including the initial blood cultures) confirmed staphylococcus aureus as the cause of the abscess and accordingly his antibiotics were changed. The antibiotic regimen was changed due to a drop in platelet count in the first few days of treatment and other investigations including trans oesophageal echocardiogram (TOE) and HIV test were all negative.

Postoperative MRI scan 3 days after operation showed significant reduction in the epidural abscess, and also

abnormal enhancement of the C5/6 intervertebral disc (Figure 3). After two weeks of recovery on the ward the power in his limbs improved to MRC grade of 4/5 in legs and 3/5 in upper limbs. The patient was transferred to a spinal rehabilitation unit where his intravenous antimicrobial regimen for a total period of 8 weeks was continued, and was followed by another 4-week course of oral suppression antibiotic therapy. The follow up MRI scan before transfer to rehabilitation unit showed complete resolution of epidural abscess and irregularity and narrowing of the C5/6 disc space. Approximately two months after intensive rehabilitation his quadriplegia recovered significantly and he was able to walk independently with mild in-coordination and significant improvement of function level in the upper limb with mild degrees of difficulty with fine movements. Follow-up review in 6 months and repeat MRI showed a good neurological recovery and complete resolution of the abscess. Currently he is back to work and apart from occasional tiredness and minor issues with his balance does not have any symptoms.

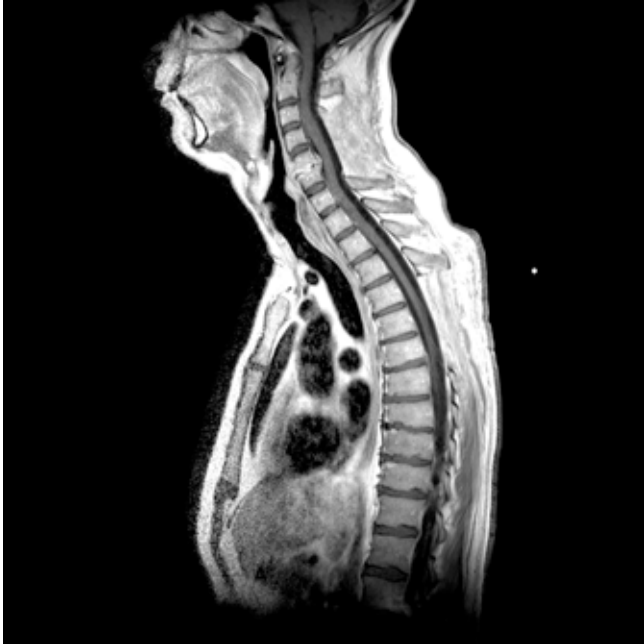## DISCUSSION:

Spinal epidural abscess, first reported by Morgagni et al. in 1761<sup>1</sup> is a relatively rare condition (0.2-1.2 of 10000 hospital admissions<sup>6, 7</sup>) with potential serious consequences. The advances in imaging technology, ageing population, use of spinal instrumentations and vascular interventions have doubled the incidence of this pathology over the last two decades<sup>6</sup>. Other risk factors including underlying disease (diabetes mellitus, alcoholism, drug abuse, etc.) and local or systemic source of infection are other possible causes of spinal epidural abscess<sup>6</sup>. Contiguous spread (in one third of cases) and haematogenous dissemination (in about half of the cases) have been described as the common mechanisms of acquiring the infection<sup>6</sup>. Staphylococcus aureus has been described as the pathogenic organism in two third of cases<sup>6, 7</sup>. Other organisms such as group B streptococcus have been described in diabetic patients<sup>5</sup>. Mechanical compression and cord infarction secondary to septic thrombophlebitis can lead to irreversible neurological deficits<sup>6</sup>. Clinical presentation can be very non-specific, but the triad of back pain, fever and neurological deficit, which are rarely seen, should raise the concern about spinal epidural abscess until proven otherwise<sup>6</sup>.

Psoas abscess with worldwide incidence of 12 cases per year 100,000 in 1992<sup>3, 8</sup>, and unknown current incidence, could per se be a challenge to diagnosis. It is thought that the incidence of psoas abscess is increasing. The median time to diagnosis of psoas abscess in literature has been reported up to 3 days<sup>3</sup>. Psoas abscess has been classified as primary (haematogenous) or secondary (neighbour structure)<sup>2</sup> with 80% of primary cases caused by Staphylococcus aureus and enteric bacteria as the most common organism in secondary cases<sup>4</sup>. Spinal manipulation has been described in the literature as one of the predisposing factors to psoas abscess<sup>2</sup>.

Our case represents the importance of early diagnosis of epidural abscess especially in conjunction with psoas abscess. Although the initial presentation of our patient was not very

typical of spinal abscess and was not fulfilling the triad of this pathology, the high degree of suspicion and abnormal laboratory findings were the initial findings leading to this diagnosis. Our patient was started on empirical IV antibiotics after obtaining relevant samples for septic screen. We feel the underlying sticky platelet syndrome was not contributing to his pathology and the recent manipulation by physiotherapist could have been a predisposing factor as per literature.



*Fig 3.* Sagittal T1-weighted scan of cervical and dorsolumbar spine after intravenous Gadolinium, three days following surgery. There has been resolution of the epidural abscess in the cervical and upper dorsal spine, with reduction in its extent in the lower dorsal and lumbar spine. Note enhancement of C5/6 intervertebral disc.

The initial MRI scan was interpreted as showing probable degenerative changes in the C5/6 disc space, due to a lack of adjacent marrow oedema and apparently chronic disc space narrowing and protrusion with osteophyte formation. In retrospect there was also prevertebral soft tissue swelling. At the time of admission, scans of the cervical spine were not obtained after intravenous Gadolinium, as the patient became unwell and had to be removed from the scanner.

MRI of the cervical spine after intravenous Gadolinium three days after surgery showed clear enhancement of the C5/6 disc, consistent with infection, and subsequent scans showed progressive disc space narrowing. It is interesting to speculate whether, if the patient had not become unstable, this enhancement might have been seen at the time of admission, leading to a diagnosis of cervical disc space infection causing spinal epidural abscess. This might have led the radiologist not to carry out axial scans of the dorsolumbar spine and thus in failure to diagnose the psoas abscesses.

It is difficult to decide whether the psoas abscesses or cervical disc space infection were the primary infection resulting in the epidural abscess. Epidural infection secondary to disc space infection would characteristically be associated with typical changes of infection in the disc and adjacent marrow on MRI, at time of presentation. Given that the patient's initial presentation for physiotherapy was with back pain, following which he developed symptoms referable to the neck, and also the lack of florid change in the C5/6 disc on the initial MRI, it is likely that the changes at C5/6 represent secondary infection of a previously degenerate disc. We are unaware of this sequence of events having been previously reported in the literature. Whether the infection originated in the lumbar paraspinal tissues or cervical disc, this case illustrates that imaging should be continued until the full extent of any intraspinal and paraspinal infection has been established. The surgical approach to this pathology in view of the extent of the abscesses helped to maintain the stability of spine in this case in accordance with near complete evacuation of abscess.

### CONCLUSION:

To our knowledge panspinal epidural abscess and paraspinal abscess with secondary cervical disc space infection has not been reported in the literature. This case report shows high clinical suspicion and early and thorough radiological investigation in similar cases are essential for ensuring the best possible outcome from surgical intervention in this group of patients.

The authors have no conflicts of interest

### REFERENCES:

1. Chen WC, Wang JL, Wang JT, Chen YC, Chang SC. Spinal epidural abscess due to *Staphylococcus aureus*: clinical manifestations and outcomes. *J Microbiol Immunol Infect* 2008; **41**: 215-21.
2. Flavin NE, Gomez M. Fever, pain, and a limp: a case of a psoas and spinal epidural abscess caused by methicillin-resistant *Staphylococcus aureus* in a diabetic patient. *J Natl Med Assoc*. 2009; **101**: 84-6.
3. Garner JP, Meiring PD, Ravi K, Gupta R. Psoas abscess - not as rare as we think. *Colorectal Dis* 2007; **9**: 269-74.
4. Gruenwald I, Abrahamson J, Cohen O. Psoas abscess: case report and review of the literature. *J Urol*. 1992; **147**: 1624-6.
5. Oblak MR, Oblak C, Stankovic S. Psoas and spinal epidural abscess in a diabetic patient--case report. *Diabetes Res Clin Pract* 2005; **68**: 274-7.
6. Rabih O, Darouiche . Spinal Epidural Abscess. *N Engl J Med* 2006; **355**: 2012-20.
7. Rigamonti D, Liem L, Sampath P, Knoller N, Namaguchi Y, Schreiberman DL, et al . Spinal epidural abscess: contemporary trends in etiology, evaluation, and management. *Surg Neurol* 1999; **52**: 189-96.
8. Taiwo B . Psoas abscess: a primer for the internist. *South Med J* 2001; **94**: 2-5.
9. Wells RD, Bebart VS . Primary iliopsoas abscess caused by community-acquired methicillin-resistant *Staphylococcus aureus*. *Am J Emerg Med* 2006; **24**: 897-8.