

Paper

Encapsulating peritoneal sclerosis – A 5 year experience

Robert Spence¹, Scott Gillespie², Maurice Loughrey^{3,4}, Keith Gardiner¹

Accepted 5 December 2012

ABSTRACT

Title: Encapsulating peritoneal sclerosis – A 5 year experience

Aim: Encapsulating peritoneal sclerosis (EPS) is a rare, life-threatening condition, characterised by a progressive, intra-abdominal inflammatory process resulting in fibrotic visceral constriction. We report the aetiology, management, and outcome of EPS in Belfast.

Method: All patients diagnosed with EPS in Belfast over the past 5 years are included. Presentation, aetiology, imaging, pathology, and outcome are retrospectively analysed and reported.

Results: 7 patients (4 males) were identified with EPS with a mean age 54 years (range 33-69). Aetiology included peritoneal dialysis (3), radiation enteritis (1), peritoneal dialysis and radiation enteritis (1), tuberculosis, cirrhosis, and beta-blocker use (1), infected aorto-bifemoral graft (1). Of the 7 patients, 5 underwent definitive surgery. Bowel conserving surgery (laparotomy, division of adhesions, excision of membrane) was performed in 4 patients. One patient required an ileocaecal resection for radiation enteritis. Median pre-operative and post-operative hospital stay were 25 and 62 days respectively. Three patients required total parenteral nutrition (TPN) pre-operatively, 3 patients post-operatively; with 4 of the 7 patients discharged on TPN. 5 out of 7 patients are alive at median follow-up of 24 months. There was no 30-day in-hospital mortality.

Conclusions: Patients with EPS often require parenteral nutrition before and after surgery. Peritoneal dialysis is a major risk factor for the development of EPS but other aetiologies should be considered. These patients have multiple co-morbidities, and operations for EPS are challenging with a high risk of peri-operative complications. Therefore these patients are best managed in a specialised unit with experience in intestinal failure surgery and access to a multi-disciplinary nutrition support team.

Key words: Peritoneal Fibrosis

INTRODUCTION

Encapsulating peritoneal sclerosis (EPS) is a rare and life-threatening condition, with a mortality of 60-93%.¹ It was first reported in 1978, when ten patients underwent surgery for an “abdominal cocoon”.² Initially known as sclerosing encapsulating peritonitis, but renamed EPS as the term ‘*sclerosing encapsulating peritonitis*’ was thought to imply infection as the major cause.¹

Peritoneal dialysis was considered responsible for the majority of EPS cases. It is now recognised that EPS is more frequent in the non-dialysis population, as a consequence of other causes of peritoneal inflammation. Non-dialysis aetiologies include previous abdominal surgery, cirrhosis, beta-blocker use, tumours with peritoneal seeding, intraperitoneal infection (including tuberculosis), endometriosis, and intraperitoneal drug administration.³

The diagnosis of EPS requires two criteria to be satisfied – clinical features of obstruction, and the demonstration, either by imaging or during surgery, that the clinical features are due to peritoneal membrane thickening, resulting in encapsulation of the bowel.⁴ EPS commonly presents with an insidious

onset of abdominal pain, anorexia, nausea, vomiting, early satiety, weight loss, altered bowel habit, and malnutrition. On examination, there may be abdominal fullness.⁵ In a surgical resection specimen, the characteristic histopathological features are of a dense laminated band of submesothelial fibrosis with mild associated chronic inflammation and, unless a second pathological process is also present, unremarkable muscular bowel wall and mucosal surface.

EPS is a complex disorder whose treatment requires multi-disciplinary input from gastroenterologists, dietitians, and surgeons. Management includes optimising nutrition, symptom control, medication, and surgery.

1 Department of Colorectal Surgery, Royal Victoria Hospital, Belfast.

2 Imaging Centre, Royal Victoria Hospital, Belfast.

3 Department of Histopathology, Royal Victoria Hospital, Belfast.

4 Northern Ireland Molecular Pathology Laboratory, Centre for Cancer Research and Cell Biology, Queen’s University, Belfast

Correspondence to Robert A J Spence

robert.spence@gmail.com

TABLE 1
Pre-operative CT findings of patients with EPS

Patient:	Aetiology of EPS:	Pre-operative CT Findings (graded + to +++ for severity):				
		Peritoneal thickening	Bowel dilatation	Nodularity	Septation	Calcification
1	Peritoneal dialysis	++	+	-	++	-
2	Radiation enteritis	+	+++	-	+	+
3	Peritoneal dialysis	+	+++	-	-	+
4	Peritoneal dialysis	+	++	-	+	+++
5	Radiation enteritis, peritoneal dialysis	+	++	-	-	+
6	TB, Beta-blocker, cirrhosis	++	++	-	+	+
7	Infected aortic graft	+	+	-	-	-

This retrospective case series reports our experience with EPS over the past 5 years in Belfast.

METHODS

This study reports all cases of EPS diagnosed and treated at Royal Victoria and Belfast City Hospitals between 2005 and 2011. Patients were identified from medical records with the diagnosis of EPS. A possible limitation of this study is that it may not represent the full spectrum of the disease, due to the difficulty of accurate diagnosis of EPS. However, the majority of cases in this locality have been referred to a single surgeon, therefore we believe that all significant cases have been included. Information regarding presentation, aetiology, imaging, pathology and management was obtained by accessing patient notes, radiology systems, and pathology results. CT scans were reviewed and graded for severity of peritoneal thickening, bowel dilatation, nodularity, septation and calcification. Each finding was graded 1+ to 4+ for severity by an independent Radiologist. Operative specimens were reviewed pathologically to assess thickness of peritoneum, chronic inflammatory infiltrate, fibroconnective proliferation and dilated lymphatics.

RESULTS

Seven patients were identified from medical records with a diagnosis of EPS, established by satisfying two criteria; bowel obstruction, and the demonstration that clinical symptoms were secondary to peritoneal membrane thickening, confirmed by imaging, surgery, or pathology. Four males and three females were identified, with a mean age of 54 years (range 33-69) at diagnosis. Confirmed aetiology included peritoneal dialysis (3 patients), radiation enteritis (1), peritoneal dialysis and radiation enteritis (1), tuberculosis, cirrhosis and beta-blocker use (1), and infected aorto-bifemoral graft (1). The four peritoneal dialysis patients had differing causes of their renal failure, including diabetes, IgA nephropathy, and mesangiocapillary glomerulonephritis. Median duration of peritoneal dialysis was 53 months (range 36-78 months).

The most common presenting symptoms were abdominal pain (6/7 patients), nausea & vomiting (6/7), and weight loss (6/7). Central abdominal fullness and change in bowel habit were

noted in 5 out of 7 patients, with only 3 patients presenting with poor appetite.

CT imaging review and grading demonstrated that peritoneal thickening and bowel dilatation were seen in all 7 patients in the series. Calcification and septations were visible on CT imaging of 5/7 patients and 4/7 patients respectively, as shown in *Table 1*. Figures 1 and 2 demonstrate dilated small bowel loops surrounded by a thin membrane in the central abdomen, and a 'clump' of dilated central small bowel loops with serosal and peritoneal calcification respectively.

Features consistent with EPS were found in the 5 patients who underwent surgery, confirming the diagnosis, as demonstrated in *Table 2*.

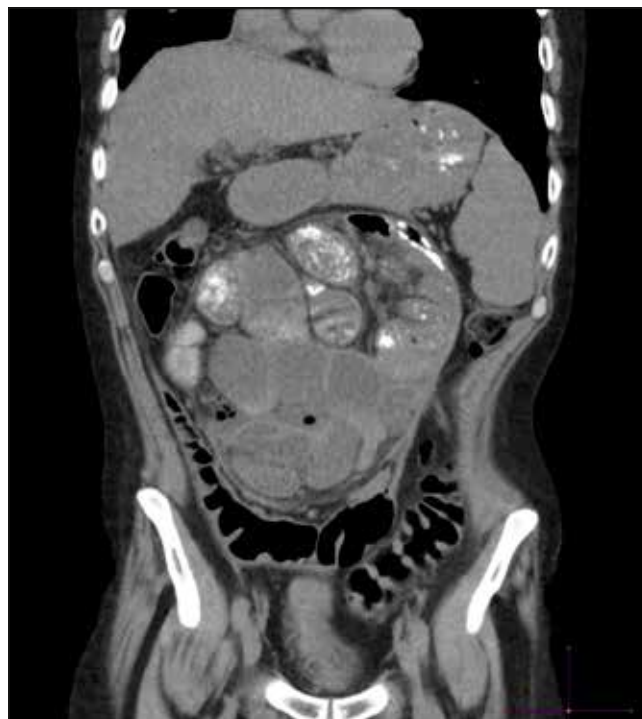

Fig 1. Coronal reformatted image from a CT scan of abdomen demonstrating dilated small bowel loops surrounded by a thin membrane in the central abdomen in keeping with encapsulating peritoneal sclerosis.

TABLE 2:

Aetiology and pathology findings of case series

Patient:	Aetiology of EPS:	Pathological features consistent with EPS:
1	Peritoneal dialysis	No pathology
2	Radiation enteritis	Yes (also signs of radiation injury)
3	Peritoneal dialysis	Yes
4	Peritoneal dialysis	Yes
5	Radiation enteritis, peritoneal dialysis	No pathology
6	TB, Beta-blocker use, cirrhosis	Yes
7	Infected aortic graft	Yes

Of the seven patients, five underwent surgery, with two patients managed conservatively. Of the five who did progress to definitive surgery, two were initially treated conservatively, with one patient receiving Tamoxifen and Prednisolone, and the second patient receiving Tamoxifen, Prednisolone, and Azathioprine, used to suppress peritonitis. Surgical management was complex and lengthy in duration - median 'skin-to-skin' time was 243 minutes (range 221-439 minutes), with an additional median of 61 minutes (range 32-63 minutes) for anaesthetic set-up time. Bowel conserving surgery (laparotomy, division of adhesions, excision of membrane) was performed except for one patient

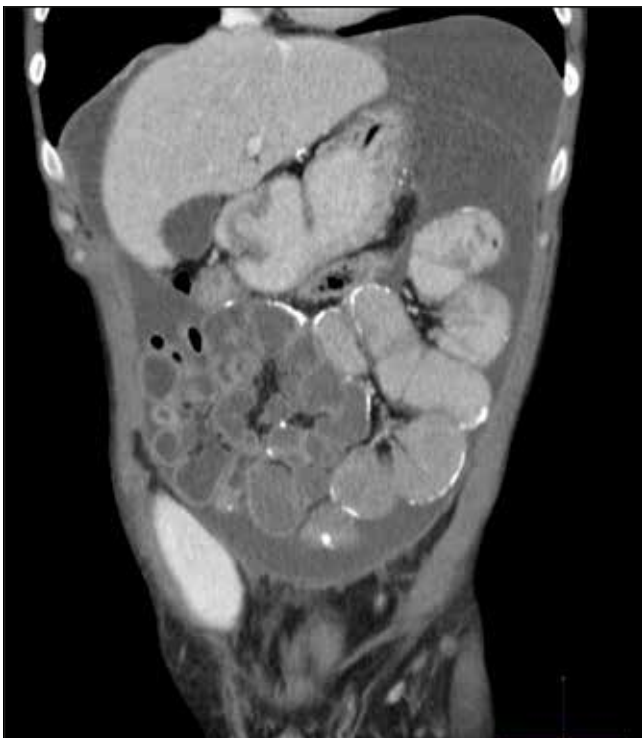

Fig 2. Coronal reformatted image from a CT scan of abdomen demonstrating a 'clump' of dilated central small bowel loops with serosal / peritoneal calcification in a patient with encapsulating peritoneal sclerosis. There is also a significant quantity of ascites.

who required an ileocaecal resection. Two patients required ileostomies. Figures 3 and 4 demonstrate intra-operative findings of fibrous tissue constricting viscera, and the classical "abdominal cocoon" respectively. Table 2 shows the pathological findings. Patient 2 underwent an ileocaecal resection where pathological resection of the small bowel showed features of both radiation enteritis and EPS.

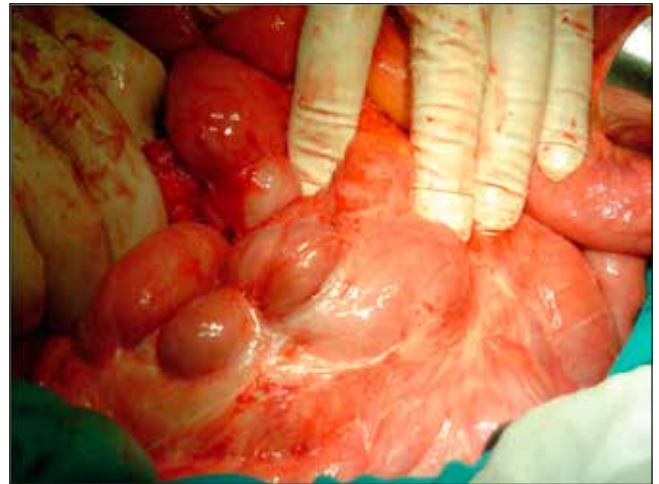

Fig 3. Intra-operative image demonstrating fibrous tissue constricting viscera, typical of EPS.

Median pre-operative and post-operative hospital stay was 25 days (range 1-105 days), and 62 days (range 17-145 days) respectively. 2 out of the 5 patients required ICU / HDU management post-operatively. Post-operative complications included central line sepsis (3 patients), high stoma output (2 patients), and drain site infection (1 patient). Two patients did not proceed to surgery due to the likelihood of not surviving the procedure as a consequence of co-morbidities – one patient with insulin-dependent diabetes, renal failure, myocardial infarction, coronary artery bypass grafting (CABG), and previous renal transplant; the second patient with insulin-dependent diabetes, renal failure, pulmonary embolus, and cervical carcinoma.

Three patients required parenteral nutrition pre-operatively, 3 patients post-operatively; with 4 of the 7 patients discharged

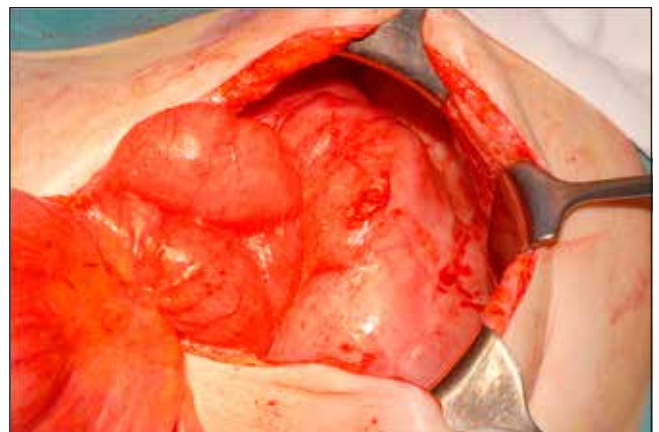


Fig 4. Intra-operative image demonstrating the classical "abdominal cocoon" found with EPS.

on TPN. With long-term follow-up over 24 months, only 1 patient has not been weaned off home TPN.

Five out of seven patients are alive at median follow-up of 24 months from diagnosis. There was no 30-day in-hospital mortality.

DISCUSSION

The clinical features of patients with EPS at initial presentation can be non-specific, with abdominal pain, weight loss, nausea and vomiting being the most common initial symptoms. It is therefore important to investigate non-specific symptoms in 'at-risk' patients, especially patients undergoing peritoneal dialysis. It has been reported that the incidence of EPS is up to 3% in patients undergoing peritoneal dialysis, and is proportional to the amount of time spent undergoing dialysis.⁶ There have been three major studies regarding incidence and time on dialysis. A Japanese study (6923 peritoneal dialysis patients) demonstrated an incidence of 0.9% of patients on peritoneal dialysis progressing to EPS.⁷ A Manchester study with 810 dialysis patients, demonstrated an incidence of 3.3%.⁸ An Australian study showed an prevalence of 0.7%, which increased progressively with the duration of peritoneal dialysis (1.9%, 6.4%, 10.8%, and 19.4% for patients on dialysis for 2, 5, 6 and 8 years respectively).⁹

With the patients who developed EPS secondary to peritoneal dialysis in our series, the median duration of peritoneal dialysis was 53 months (range 36-78 months).

The aetiology of this difficult condition is unclear, with a 'two-hit' hypothesis having been proposed.^{4,10} This hypothesis suggests disruption of peritoneal physiology and histology by a long duration of continuous exposure to hypertonic glucose dialysis solutions. A 'second hit' then provokes the full syndrome of EPS, with the second hit being due to recurrent peritonitis, exposure to infections such as tuberculosis, or even the paradox of discontinuing peritoneal dialysis (undergoing renal transplantation, or converting to haemodialysis). In this series, two patients suffered frequent attacks of peritonitis and required increasing glucose content in their dialysis solutions.

Augustine and colleagues propose plasma exudation, fibrin deposition and subsequent fibrosis as the basis of the pathogenesis.⁴ Loss of the peritoneal physiological responses of production of fibrinolytic agents increases the risk of fibrinous adhesions. Furthermore, over-expression of TGF- β 1 is also associated with adhesions.

Glucose in dialysis fluid may have a role in peritoneal mesenchymal cell malfunction, stimulating angiogenesis with TGF- β (transforming growth factor β) and vascular endothelial growth factor (VEGF) production by mesothelial cells. This however, does not explain those cases not associated with dialysis.

A high index of suspicion is fundamental to diagnosis, especially with patients undergoing peritoneal dialysis suffering from intermittent sub-acute bowel obstruction

and weight loss. The literature supports CT (with a scoring system)¹¹ as the best imaging modality, although dynamic MRI may prove beneficial in the future.¹²

Management of EPS is complex, requiring a multidisciplinary approach. Nutritional support is central, with involvement of specialist dieticians from the outset. Nutrition can be complemented by oral supplements, enteral, or parenteral feeding. This can be successful in maintaining nutrition and minimising obstructive symptoms. Nutritional support should begin early, and may be required for a prolonged period.¹⁰ These patients will most likely also require post-operative nutritional support, as shown in our case series, where 4/7 patients were discharged on home TPN. However, only 1 patient has not been successfully weaned off TPN 24 months post-surgery.

There have been mixed data published regarding medical treatment of EPS. Corticosteroids have been the first line medical management with little evidence to support their use.⁶ Tamoxifen has been used with some theoretical basis – due to its anti-TGF- β properties – and is now the mainstay of medical therapy even though the controlled data are limited.^{13,14} A randomised controlled trial has not been carried out probably because of small numbers and difficulty of diagnosis. There is some evidence (mostly case reports), that immunosuppressants, such as Azathioprine or Ciclosporin, are effective in EPS. However, it must be noted, that there is a high incidence of EPS in renal transplant patients, who are immunosuppressed.¹⁵

Surgery should be performed prior to complete obstruction, and before the patient becomes nutritionally depleted. It requires a high index of suspicion of EPS, with the role of surgery being to restore gut function, relieve obstructive symptoms, improve nutrition and may be life-saving. It involves undertaking extensive enterolysis and peritonectomy. The aim is to perform the peritonectomy without enterotomy, or bowel resection, and without a stoma. Morbidity can be an issue with these complex cases, with complications of bleeding, intra-abdominal collections, recurrent obstruction, fistula and sepsis. This is difficult, time consuming surgery.

Prognosis is poor, especially with a late diagnosis. There is a mortality rate between 25% and 55% in the first year.^{6,16} In our study, two out of seven patients died within 2 years following their initial diagnosis. Emergency surgery for complete intestinal obstruction must be avoided, with a higher mortality of 60-93%.

Augustine and colleagues in both 2009 and 2012, have clearly indicated these complex patients are challenging to manage.^{4,10} These patients need access to an experienced nutrition support team for potentially pre- and post-operative TPN. It is important to avoid emergency surgery in these malnourished patients. If they require surgery, this should be done in a dedicated centre with an experienced intestinal failure surgeon with access to a full team of multi-disciplinary specialists (radiology, nursing, dietetics), including access to

home TPN. There should be a national registry of these rare patients to collate outcome and research data.

In England, centres in Manchester and Cambridge are designated by the National Specialist Commissioning Group⁴ for treatment of patients with this rare disorder since 2009.

CONCLUSION

These patients often require nutritional support before and after surgery. Peritoneal dialysis is a risk factor for developing EPS but other aetiologies should be considered. These patients are complex and are best managed in a specialised surgical unit with access to nutritional support. This is difficult surgery and there is merit in two experienced consultants operating together as has been recommended for specialised surgery for intestinal failure.¹⁷

The authors have no conflicts of interest.

REFERENCES

1. Kawaguchi Y, Kawanishi H, Mujais S, Topley N, Oreopoulos DG. Encapsulating peritoneal sclerosis: definition, etiology, diagnosis, and treatment. International Society for Peritoneal Dialysis Ad Hoc Committee on Ultrafiltration Management in Peritoneal Dialysis. *Perit Dial Int* 2000;**20 Suppl 4**:S43-55.
2. Kawaguchi Y, Traaneus A. A historical review of encapsulating peritoneal sclerosis. *Perit Dial Int* 2005;**25 Suppl 4**:S7-13.
3. Pollock CA. Diagnosis and management of encapsulating peritoneal sclerosis. *Perit Dial Int* 2001;**21 Suppl 3**:S61-6.
4. Augustine T, Brown PW, Davies SD, Summers AM, Wilkie ME. Encapsulating peritoneal sclerosis: clinical significance and implications. *Nephron Clin Pract* 2009;**111(2)**:c149-54; discussion c54.
5. Nakamoto H. Encapsulating peritoneal sclerosis--a clinician's approach to diagnosis and medical treatment. *Perit Dial Int* 2005;**25 Suppl 4**:S30-8.
6. Kawanishi H, Kawaguchi Y, Fukui H, Hara S, Imada A, Kubo H, et al. Encapsulating peritoneal sclerosis in Japan: a prospective, controlled, multicenter study. *Am J Kidney Dis* 2004;**44(4)**:729-37.
7. Nomoto Y, Kawaguchi Y, Kubo H, Hirano H, Sakai S, Kurokawa K. Sclerosing encapsulating peritonitis in patients undergoing continuous ambulatory peritoneal dialysis: a report of the Japanese Sclerosing Encapsulating Peritonitis Study Group. *Am J Kidney Dis* 1996;**28(3)**:420-7.
8. Summers AM, Clancy MJ, Syed F, Harwood N, Brenchley PE, Augustine T, et al. Single-center experience of encapsulating peritoneal sclerosis in patients on peritoneal dialysis for end-stage renal failure. *Kidney Int* 2005;**68(5)**:2381-8.
9. Rigby RJ, Hawley CM. Sclerosing peritonitis: the experience in Australia. *Nephrol Dial Transplant* 1998;**13(1)**:154-9.
10. van Dellen D, Augustine T. Encapsulating peritoneal sclerosis. *Br J Surg* 2012;**99(5)**:601-2.
11. Tarzi RM, Lim A, Moser S, Ahmad S, George A, Balasubramaniam G, et al. Assessing the validity of an abdominal CT scoring system in the diagnosis of encapsulating peritoneal sclerosis. *Clin J Am Soc Nephrol* 2008;**3(6)**:1702-10.
12. Wright B, Summers A, Fenner J, Gillott R, Hutchinson CE, Spencer PA, et al. Initial observations using a novel "cine" magnetic resonance imaging technique to detect changes in abdominal motion caused by encapsulating peritoneal sclerosis. *Perit Dial Int* 2011;**31(3)**:287-90.
13. Guest S. Tamoxifen therapy for encapsulating peritoneal sclerosis: mechanism of action and update on clinical experiences. *Perit Dial Int* 2009;**29(3)**:252-5.
14. Korte MR, Fieren MW, Sampimon DE, Lingsma HF, Weimar W, Betjes MG. Tamoxifen is associated with lower mortality of encapsulating peritoneal sclerosis: results of the Dutch Multicentre EPS Study. *Nephrol Dial Transplant* 2011;**26(2)**:691-7.
15. Korte MR, Habib SM, Lingsma H, Weimar W, Betjes MG. Posttransplantation encapsulating peritoneal sclerosis contributes significantly to mortality after kidney transplantation. *Am J Transplant* 2011;**11(3)**:599-605.
16. Kawanishi H, Moriishi M. Epidemiology of encapsulating peritoneal sclerosis in Japan. *Perit Dial Int* 2005;**25 Suppl 4**:S14-8.
17. Carslon G, Gardiner KR, McKee R, MacFie J, Vaizey C. The surgical management of patients with acute intestinal failure. *Issues in Professional Practice: Association of Surgeons of Great Britain and Ireland*, 2010.