

Paper

Endoscopic Ultrasound in Barrett's Oesophagitis with Dysplasia

Andrew Wray¹, Paul Rice², Mark Love¹

Accepted 30 January 2012

Purpose: With the advent of conservative therapies including photodynamic therapy and endoscopic mucosal resection for Barrett's and high grade dysplasia, accurate staging has become increasingly important. We report our experience with endoscopic ultrasound (EUS) in these patients.

Materials and Methods: Retrospective review of 25 consecutive patients referred for EUS for assessment of Barrett's with high grade dysplasia and /or stricture or polyp. The findings were compared with subsequent surgical pathology, or endoscopy and biopsy follow up.

Results: Nine patients were found to have invasive tumour on EUS and this was confirmed in all 9 either by oesophagectomy, OGD and oncology follow up, or by endoscopic mucosal resection.

Eight patients underwent oesophagectomy, 5 for invasive tumour and 3 for dysplasia only, with pathological agreement with EUS findings in 7 out of 8 cases. The one discrepancy was a EUS case of mucosal thickening only with no invasion, but pathology showed a T1 lesion.

Thirteen patients with no evidence of invasion were managed conservatively, with 11 patients being followed up for 6-12 months with serial OGD and biopsy, and no cases of more invasive disease occurring.

Therefore, in our experience the sensitivity, specificity and positive predictive value of EUS in complex Barrett's is 90%, 100% and 100% respectively.

Conclusion: EUS is valuable in the assessment of high grade dysplasia in cases where conservative therapy is being considered, defining those with more deeply invasive tumour for whom radical treatment is the only option.

Key Words: Endoscopic ultrasound, Barrett's metaplasia, Oesophagus

INTRODUCTION

Barrett's oesophagitis is defined as metaplasia within the distal oesophagus from squamous to columnar epithelium in response to prolonged gastro-oesophageal reflux. This has the potential to develop dysplasia and subsequently invasive malignancy. The risk of adenocarcinoma in simple Barrett's has been estimated at 1% per year, however with high grade dysplasia this rises to 4.7%. This risk is also elevated where Barrett's is associated with a stricture or mass¹.

Previously, high grade dysplasia within an area of Barrett's was an indication, in suitably fit patients, for oesophagectomy. This however has a significant morbidity and mortality rate. Recently, endoscopic treatments such as photodynamic therapy (PDT), which involves the administration of various photosensitive agents and subsequent laser exposure, as well as endoscopic mucosal resection (EMR) have been developed. These allow high grade dysplasia, or in some cases early invasive malignancy, to be managed more conservatively with similar outcome to oesophagectomy^{2,3}.

This is dependent on accurate staging as more deeply invasive disease is not adequately managed with local treatments and can often be missed by endoscopic biopsy alone.⁴

Endoscopic ultrasound (EUS) is well documented to accurately demonstrate the layers of the oesophageal wall (Figure 1), leading to accurate local staging of malignant oesophageal disease^{5,6}.

The purpose of this study was to evaluate our experience of the use of EUS in patients with Barrett's oesophagitis and dysplasia.

MATERIALS AND METHODS

We retrospectively reviewed our use of EUS in twenty five consecutive cases of complex Barrett's oesophagitis, that is those associated with high grade dysplasia, or dysplasia with a mass or stricture. These cases were performed by two consultant radiologists with an interest in EUS in two centres between January 2005 and September 2007 using radial electronic echoendoscopes (Pentax EG/3630UR, Hitachi

¹ Imaging Centre, The Royal Victoria Hospital, Grosvenor Road, Belfast BT12 6BA ².Department of Radiology, Craigavon Area Hospital, 68 Lurgan Road, Portadown, BT63 5QQ

Correspondence to Dr Love
mark.love@belfasttrust.hscni.net

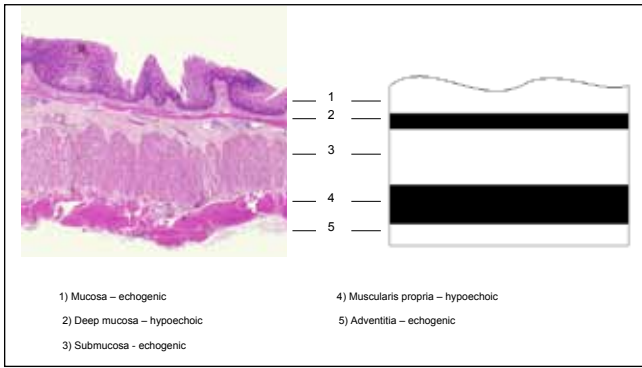


Fig 1. Histological and schematic findings of normal oesophageal wall at EUS

Medical Systems, UK and Olympus MH 908, Olympus, USA). The radiology, pathology and endoscopy records of these patients were reviewed. The EUS findings were compared with any subsequent oesophagectomy pathology specimen, or with subsequent endoscopy and biopsy follow up.

The local ethics committee was consulted but advised that full ethical approval was not required for such a retrospective study.

RESULTS

25 consecutive patients who had undergone EUS were studied. This comprised 22 males and 3 females, with a mean age of 63 years (range 37 – 83 years). All were referred for assessment of known Barrett's oesophagus. The indications are summarised in Figure 2.

Indication	Number of patients
High grade dysplasia	15
Mass or stricture	5
Suspicious biopsy	3
Dysplasia, query grade	1
Previous PDT	1

Fig 2. Indication for EUS

All patients had proven Barrett's oesophagitis in addition to the above.

The EUS in 9 of these patients was reported as showing probable invasive tumour, and a T stage was assigned (Figures 3-5). Asymmetric or focal thickening of the mucosal layer on EUS was deemed T1 disease, with disease which invading the muscularis propria (T2), and beyond (T3, T4) being more easily recognised. Invasive tumour was confirmed in all 9 cases. 5 underwent oesophagectomy with pathological confirmation. One patient underwent endoscopic mucosal resection where the pathology confirmed the EUS findings of a T1 lesion. 3 patients underwent oncology and palliative care management after subsequent repeat endoscopic biopsy had indicated the presence of invasive tumour, again confirming the EUS findings.

In 16 cases, no significant abnormality or only slight generalised mucosal thickening was seen on EUS. In one

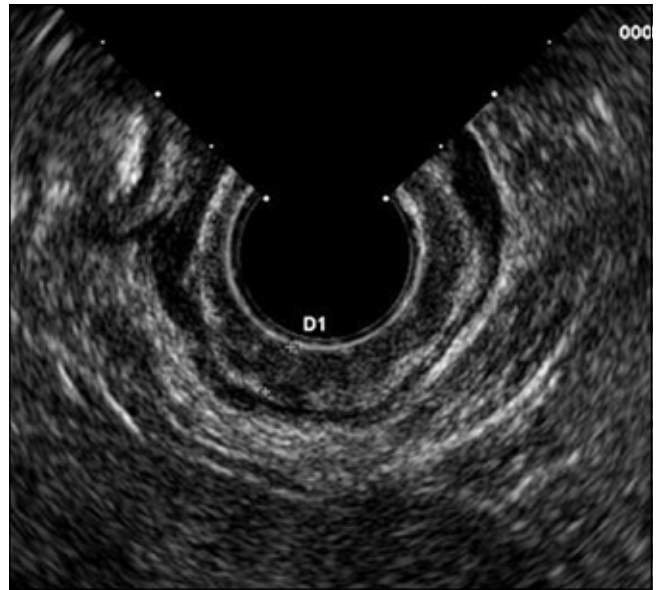


Fig 3. T1 lesion
T1 lesion, with hypoechoic muscularis propria layer be intact throughout

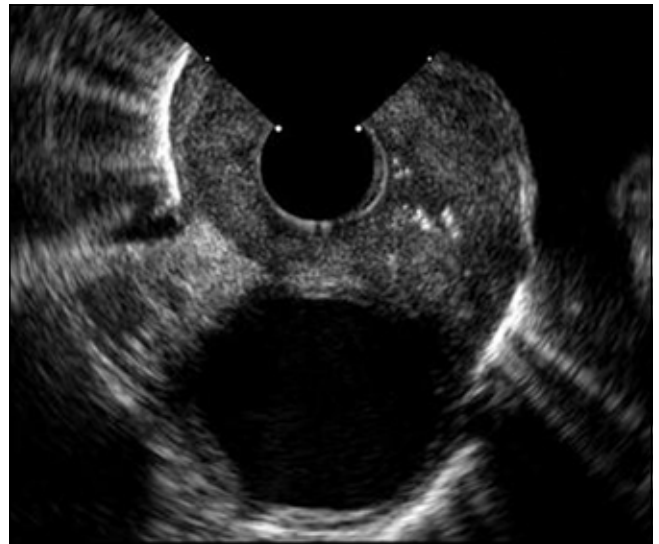

Fig 4. T4 lesion
T4 lesion, with mass seen to invade aortic wall (hypoechoic aorta seen at 6 o'clock, normal five layered oesophageal wall replaced by mass)

EUS stage	n = 9
T1	4
T2	3
T3	1
T4	1

Fig 5. T stage assigned by EUS to those in which invasive tumour was suspected.

of these cases, where the indication was Barrett's and an associated polyp, the findings were less conclusive. There was EUS suspicion of muscularis mucosa invasion, however this was a complex case with a history of oesophageal surgery as an infant, and the subtle EUS findings overall were assessed as

not being significant. 13 patients in this EUS “non invasive” group were treated conservatively. 11 of these were followed up with serial endoscopy and biopsy for between 6 months and 1 year. The other 2 patients were not followed up with serial endoscopy because of medical comorbidity. No cases of invasive tumour occurred in these 13 patients up to one year after the EUS examination. One conservatively managed patient who underwent PDT subsequently developed invasive tumour, however this occurred 29 months after the EUS examination. Only 3 patients underwent oesophagectomy in this group. High grade dysplasia was confirmed pathologically in 2 cases. There was however 1 case in which the pathology showed one small focus of invasion consistent with a T1 tumour.

Of the total 25 patients, 8 subsequently underwent oesophagectomy. The pathology matched the EUS findings in 7 of these cases, 5 of which had invasive malignancy and 2 had high grade dysplasia only. Therefore, comparing our EUS findings to histology or prolonged follow up of 6 months to 1 year, EUS has a sensitivity of 90%, a specificity of 100% and a positive predictive value of 100% for invasive disease not suitable for conservative management (Figure 6).

	No. of Patients
EUS true +ve (pathology or clinical confirmation)	9
EUS false +ve (pathology confirmation)	0
EUS false –ve (pathology confirmation)	1
EUS true –ve (pathology or 6-12 months follow up)	13

Fig 6. Summary of results

Sensitivity 90%, Specificity 100%, Positive predictive value 100%

DISCUSSION

The finding of high grade dysplasia in an area of Barrett’s oesophagitis was previously an indication for oesophagectomy. More recently, endoscopic treatments including photodynamic therapy (PDT) and endoscopic mucosal resection (EMR), have been shown to be effective in the management of high grade dysplasia and indeed superficial carcinomas. Recent NICE guidelines have stated that such treatments have become established and PDT has been shown to downgrade high grade dysplasia in 77-98% of cases⁷. However, in a suitably fit patient, oesophagectomy is still the gold standard treatment for Barrett’s oesophagitis with high grade dysplasia.

Barrett’s oesophagitis with dysplasia is traditionally followed up and staged by serial OGD and biopsy for the early detection of invasive disease. There is however a significant sampling error with this. Falk et al showed that invasive tumour was present in up to 40% of oesophagectomy specimens carried out for what was believed to be high grade dysplasia only on multiple endoscopic biopsies- ie. biopsy alone significantly under calls more invasive disease⁴. This is dramatically illustrated by one of our cases referred with high grade dysplasia only, which was found on EUS to have a T4 tumour.

EUS is able to delineate the separate histological layers of the oesophagus and has become well established as the gold standard method for preoperative local staging of oesophageal carcinoma.

EUS has not been shown to be effective in diagnosing dysplasia within an area of Barrett’s and it is not recommended for this purpose^{8,9}. It is however indicated where dysplasia is established and conservative (non-surgical) treatment is being considered.

In our study we have compared our EUS findings to the standard of either histology or prolonged clinical follow up. We have used a time scale of 6 – 12 months as our follow up standard because these patients undergo OGD and biopsy follow up with a frequency ranging from 3 monthly to annually depending on clinical suspicion. The development of invasive disease from high grade dysplasia is a continuum and therefore to compare the EUS findings with more prolonged follow up is not relevant. This is illustrated by one conservatively managed case, treated with PDT, that ultimately developed invasive disease. This occurred 29 months after the EUS, but this does not represent a misdiagnosis as the EUS findings are only relevant for the initial decision about conservative management.

Also, although a number of these patients underwent photodynamic therapy, it can still be concluded that the EUS findings were accurate as photodynamic therapy is only effective at treating mucosal and early submucosal disease. Therefore if a case with more advanced disease had been missed on EUS it would have been expected to re-present with more invasive disease.

The EUS findings correlated with the surgical pathology in 7 out of 8 cases and the one discrepancy was an under called area of submucosal invasion (T1 lesion). This case does however highlight some of the limitations of EUS in Barrett’s with early cancer, and raises issues as to our future management of these patients.

The difficulty of EUS is distinguishing between background simple Barrett’s inflammatory change and early mucosal invasive tumour, both of which will show thickening of the mucosal layer only on EUS.

If conservative management is being considered then knowing the precise degree of submucosal extension is important because of the risk of lymph node metastases. For disease limited to the mucosa (T1a) this risk is virtually 0%, however for submucosal disease (T1b) this rises to 16-22%^{10, 11}. Obviously local treatments are not suitable for cases where there is significant risk of lymph node metastases.

Endoscopic ultrasound is excellent at diagnosing invasive disease which is T2 and beyond. However EUS is well recognised to be limited in distinguishing between high grade dysplasia and T1a and T1b disease. High frequency EUS probes (20-30MHz) have been advocated for this however a number of studies have not shown this to be accurate in the detection of T1b disease¹²⁻¹⁴. May et al¹⁵ showed the diagnostic accuracy of submucosal staging with high resolution endoscopy and high resolution EUS to be similarly inaccurate, with sensitivities of only 56% and 48% respectively.

Endoscopic mucosal resection should therefore be considered in all potentially conservatively managed cases. EMR provides additional pathological staging, in particular providing accurate information with respect to submucosal invasion, were EUS underperforms¹⁶

EMR has also been shown to adequately treat high grade dysplasia as well as certain favourable cases of T1a disease. A recent review by the Society of Thoracic Surgeons concluded that it was reasonable to treat discrete mucosal disease with EMR. However they also stated that as Barrett's is often multifocal this should be complemented with a mucosal ablative procedure, for example PDT, to completely eradicate disease¹⁷.

CONCLUSION

Despite our promising figures we recognise, in common with others, the inability of EUS to distinguish dysplasia from early invasive tumour, even that involving submucosa. Given this it seems unlikely that our present level of success could be consistently sustained over a larger number of cases.

Clearly the weakness of this study relates to the small patient numbers and the high rate of conservative management preventing further definitive pathological correlation in more of the cases.

However, as conservative treatments become increasingly used for the treatment of high grade dysplasia in Barrett's oesophagitis, and given the high positive predictive value of EUS for the diagnosis of more deeply invasive disease, the authors feel that EUS retains an important role in patients with high grade dysplasia prior to EMR or PDT, in detecting unexpectedly advanced disease which clarifies the need for surgery or neoadjuvant treatment.

The authors have no conflict of interest.

REFERENCES

- Murray L, Watson P, Johnston B, Sloan J, Mainie IM, Gavin A. Risk of adenocarcinoma in Barrett's oesophagus: population based study. *BMJ*. 2003;**327**(7414):534-5
- Overholt BF. Results of photodynamic therapy in Barrett's esophagus. A review. *Can J Gastroenterol*. 1999;**13**(5):393-6
- Ell C, May A, Gossner L, et al. Endoscopic mucosal resection of early cancer and high-grade dysplasia in Barrett's esophagus. *Gastroenterology*. 2000;**118**(4):670-7
- Falk GW, Rice TW, Goldblum JR, Richter JE. Jumbo biopsy forceps protocol still misses unsuspected cancer in Barrett's esophagus with high grade dysplasia. *Gastrointest Endosc*. 1999;**49**(2):170-6
- Botet JF, Lightdale CJ, Zauber AG, Gerdes H, Umacher C, Brennan MF. Preoperative staging of esophageal cancer: comparison of endoscopic US and dynamic CT. *Radiology*. 1991;**181**(2):419-25
- Zhang X, Watson DI, Lally C, Bessell JR. Endoscopic ultrasound for preoperative staging of esophageal carcinoma. *Surg Endosc*. 2005;**19**(12):1618-21.
- National Institute for Clinical Excellence NHS. Photodynamic therapy for in Barrett's oesophagus. Interventional procedure guidance 350. NICE Guidelines. June 2010. Available from: <http://www.nice.org.uk/nicemedia/live/11131/49327/49327.pdf>. Last accessed March 2012.
- Srivastava AK, Vanagunas A, Kamel P, Cooper R. Endoscopic ultrasound in the evaluation of Barrett's esophagus: a preliminary report. *Am J Gastroenterol*. 1994;**89**(12):2192-5.
- Savoy AD, Wallace MB. EUS in the management of the patient with dysplasia in Barrett's esophagus. *J Clin Gastroenterol*. 2005;**39**(4):263-267
- Holscher AH, Bollschweiler E, Schneider PM, Siewert JR, et al. Early adenocarcinoma in Barretts oesophagus. *Br J Surg* 1997; **84**(10): 1470-3.
- Feith M, Stein HJ, Siewert JR. Pattern of lymphatic spread of Barrett's cancer. *World J Surg*. 2003; **27**(9): 1052-7.
- Chak A, Canto M, Stevens PD, Lightdale CJ, Van de Mierop F, Cooper G, et al. Clinical applications of a new through-the-scope ultrasound probe: prospective comparison with an ultrasound endoscope. *Gastrointest Endos* 1997; **45**(3): 291-5.
- Chelmaly M, Scalone O, Durivage G, Napoleon B, Pujol B, Lefort C, et al. Miniprobe EUS in the pretherapeutic assessment of early esophageal neoplasia. *Endoscopy* 2008; **40**(1): 2-6.
- Rampado S, Bocus P, Battaglia G, Ruol A, Portale G, Ancona E. et al. Endoscopic ultrasound: accuracy in staging superficial carcinomas of the esophagus. *Ann Thorac Surg*. 2008; **85**(1): 251-6.
- May A, Gunter E, Roth F, Gossner L, Stolte M, Vieth M, et al. Accuracy of staging in early oesophageal cancer using high resolution endoscopy and high resolution endosonography: a comparative, prospective, and blinded trial. *Gut*. 2004 May; **53**(5): 634-40.
- Larghi A, Lightbridge CJ, Momeo L, Bhagat C, Okpara N, Rotterdam H, et al. EUS followed by EMR for staging of high-grade dysplasia and early cancer in Barrett's esophagus. *Gastrointestinal Endoscopy*. 2005; **62**(1):16-23.
- Fernando HC, Murthy SC, Hofstetter W, Shrager JB, Bridges C, Mitchell JD, et al. The Society of Thoracic Surgeons Practice Guideline Series: Guidelines for the management of Barrett's esophagus with high-grade dysplasia. *Ann Thorac Surg*. 2009; **87**(6): 1993-2002